

---

COMUNICACIONES BREVES

---

*Tricuspid atresia associated with common arterial trunk and 22q11 chromosome deletion*

Carlos Alva,\* Felipe David,\* Martha Hernández,\* Rubén Argüero,\*\* José Ortigón,\* Arturo Martínez,\* Diana López,\* Santiago Jiménez,\* Agustín Sánchez\*

**Summary**

The case of a four-months old male with coexistent tricuspid atresia and common arterial trunk is presented. The diagnosis was made by cardiac catheterization and selective angiocardiography. Clinical considerations are discussed and the review of the available literature reveals this patient to be the tenth case reported of this very unusual association of cardiovascular defects, and the first with positive deletion of the 22q11 chromosome.

**Key words:** Tricuspid atresia and common arterial trunk. Conotruncal malformations. Absent right atrioventricular connection. Chromosome deletion.

**Palabras clave:** Atresia tricuspídea. Tronco arterial común. Malformación troncoconal. Ausencia de conexión atrioventricular derecha. Delección 22q11.

**Introduction**

**T**he combination of absent right atrioventricular connection, better known as tricuspid atresia with common arterial trunk is extremely rare. The first case reported with this exceptional association dated in 1974 by Tandon;<sup>1</sup> by the end of year 2000 only nine well documented cases had been reported.<sup>2-9</sup> The purpose of this communication is to report another case of an infant with this association, and the first with positive chromosome 22q11.

**Resumen**

ATRESIA TRICUSPÍDEA Y TRONCO ARTERIOSO COMÚN

Se presenta el caso de un paciente masculino de cuatro meses de edad con atresia tricuspídea asociada a tronco arterial común. El diagnóstico se corroboró con cateterismo cardíaco y angiocardiografía selectiva. Se analiza la expresión clínica de esta excepcional asociación y se hace una revisión de la literatura. Este es el décimo caso publicado con esta inusual asociación de lesiones cardíacas y el primero con delección del cromosoma 22q11.

(Arch Cardiol Mex 2003; 73:271-274).

**Case report**

A four-months-old male weighing 3.9 kg, was referred to our congenital heart diseases department, with a history of mild cyanosis and dyspnea on effort since he was 4 weeks old, his only brother had been corrected of Tetralogy of Fallot. Physical examination revealed no particular phenotype and disclosed mild nailbed cyanosis. Capillary arterial oxygen saturation was 78%. Blood pressure was 88/42 mm Hg in both arms and legs. There was a 2/6 systolic murmur at the

\* Congenital Heart Diseases Department.

\*\* Cardiovascular Surgery Division, Cardiology Hospital, National Medical Center, Siglo XXI. Cuauhtemoc Avenue 330, Col. Doctores, Mexico City, CP 06720 México.

Correspondencia: Carlos Alva MD, Chief of Congenital Heart Diseases Department, Cardiology Hospital, National Medical Center, Siglo XXI. Cuauhtemoc Avenue 330, Col. Doctores, Mexico City, CP 06720 México. Tel. 5627 69 00 Ext. 2500. E-mail: echoca@yahoo.com

Recibido: 15 de abril de 2003

Aceptado: 6 de junio de 2003

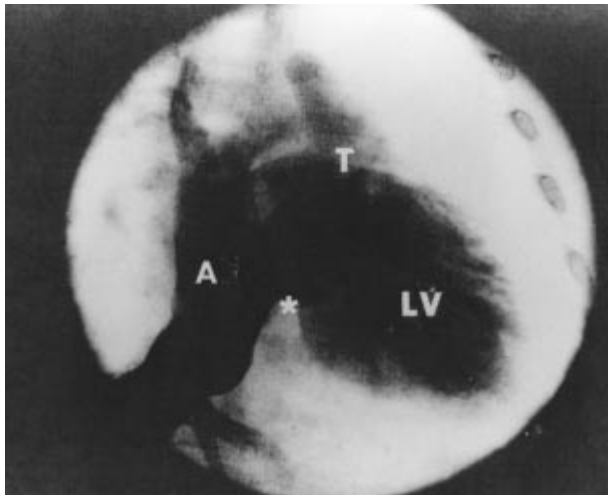


Fig. 1a.

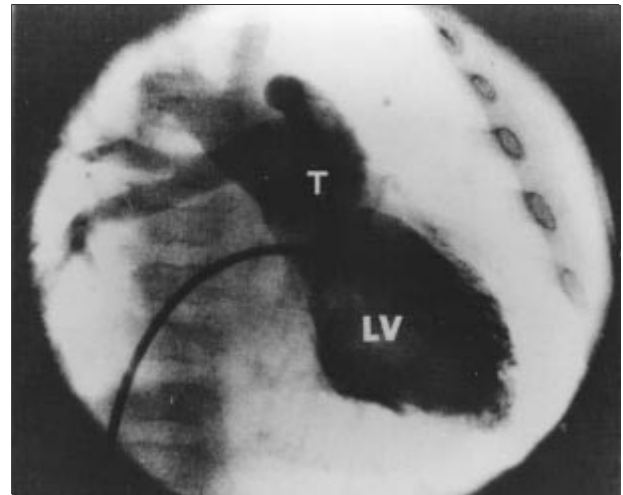
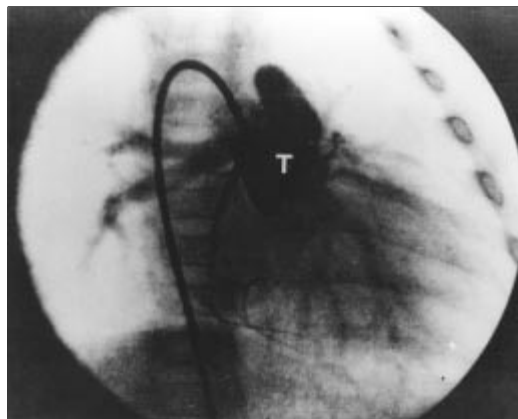


Fig. 1b.

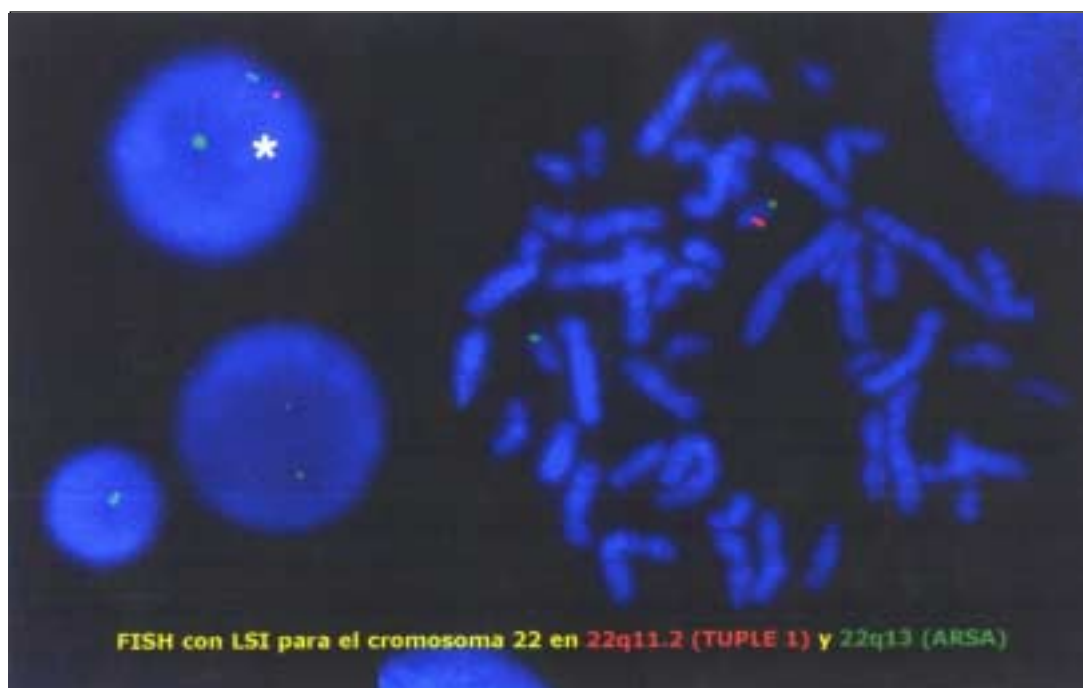
**Fig. 1. (a)** Angiogram in the AP projection in the right atrium (A). Note the absence of right atrioventricular connection (asterisk), the contrast crossing the atrial septal defect into the left atrium, left ventricle (LV) and common arterial trunk (T). **(b)** Angiogram in the left ventricle, the contrast progresses slightly through the ventricular septal defect. Note the filling of the common arterial trunk (T) with right aortic arch.



**Fig. 2.** Angiogram in AP projection in the common arterial trunk (T). Note that the left pulmonary artery arises above the right pulmonary artery. The truncal valve is competent.

left sternal border and single second sound. The X-ray examination revealed moderate cardiomegaly and increased pulmonary vascular markings. The electrocardiogram showed a QRS axis at  $-30^\circ$ , right atrium enlargement and left ventricular hypertrophy. Echocardiography showed atrial *situs solitus*, absent right atrioventricular connection, subarterial septal defect and common arterial trunk. Right and left cardiac catheterization confirmed the echocardiographic findings and revealed the following pressures, (in mm Hg): in the right atrium, mean 4; left atrium, mean

3, left ventricle, 75/6; right ventricle 75/5; common arterial trunk 60/35/40; right pulmonary artery 28/14/19; left pulmonary artery 30/15/20. A systolic gradient of 32 and 30 mm Hg was obtained between the common arterial trunk and the right and left branches of the pulmonary artery, respectively. The ratio of pulmonary to systemic flow ratio was 1.9:1. Selective angiography showed the typical sequence of tricuspid atresia in the right atrium (Fig. 1a); and the common arterial trunk, emerging mainly from the left ventricle, and a tiny left to right shunt through a subarterial septal defect in the left ventricle (Fig. 1b). The common arterial trunk showed a short pulmonary trunk with right aortic arch and no truncal valve regurgitation (Fig. 2). The ejection fraction of the left ventricle was 66%. The two cases with conotruncal malformation in the patient's family, led us to search for microdeletion in the 22q11 region in the patient. By fluorescent *in situ* hybridization, the chromosome 22q11 deletion was positive (Fig. 3). The case was discussed with the staff of the cardiovascular division. It was considered that the patient has a "natural" pulmonary banding in both pulmonary arteries due to the mild pulmonary stenosis producing a compensated condition. The patient is on digoxin and furosemide. The perspective is to separate the pulmonary artery from the pulmonary trunk and to perform a systemic-to-pulmonary shunt as a first step, to consider, in the



**Fig. 3.** Fluorescent *in situ* hybridization (FISH), chromosomes in metaphase from peripheral blood sample. The asterisk points out the deletion: a mark is missed.

future, total cavopulmonary derivation once the pulmonary pressure and resistance are low enough.

### Discussion

At the beginning of 1991, there were 6 cases with this association, all of them died before reaching three months of age due to cardiac failure and cyanosis.<sup>1-6</sup> The seventh case reported, was the first successful palliation made by Sreeram et al., this palliation included disconnection of the pulmonary arteries from the common arterial trunk and systemic to-pulmonary-shunt, however, no data are available on the follow up.<sup>7</sup> In 1999, an atrial septectomy was created as palliation in a newborn with these malformations, however the patient died few days after the procedure.<sup>8</sup> The last case reported before our case was successful. The correction was performed in three steps. First, the pulmonary arteries were disconnected from the arterial trunk combined with a systemic-to-pulmonary shunt, an atrial septectomy was also done. In the second step consisted of a hemi-Fontan procedure and in the third an last

operation, a fenestrated total cavopulmonary derivation was completed. The boy is now 8 years old and doing well.<sup>9</sup> Review of the literature revealed that the last cases were in *situs solitus* and levocardia whereas the first was in dextrocardia. Cardiac failure, cyanosis, left QRS deviation and cardiomegaly with increased pulmonary soon after birth were common features.<sup>1-9</sup> Two-dimensional color Doppler echocardiography should be enough to establish the diagnosis, however, pulmonary vascular pressures and resistance must be assessed by cardiac catheterization. The unique clinical picture of this case is related with the moderate pulmonary stenosis, protecting the patient from cardiac failure and allowing sufficient arterial oxygen saturation. On the other hand, 22q11 chromosome deletion has been well documented in trunco-conal malformations.<sup>10,11</sup> Momma et al.<sup>12</sup> reported that 5 of 15 consecutive common arterial trunk patients were positive for 22q11 deletion.

This patient is the tenth reported case of this exceptional association of heart defects and the first with 22q11 chromosome deletion.

## References

1. TANDON R, MOLLER JH, EDWARDS JE: *Persistent truncus arteriosus associated with tricuspid atresia*. Min Med 1974; 57: 448-450.
2. AREIAS JC, LOPES JM: *Common arterial trunk associated with absence of one atrioventricular connection*. Int J Cardiol 1987; 17: 329-332.
3. BHARATI S, McALLISTER HA JR, TATOLES CJ, MILLER RA, WEINBERG M, BUCHELERS HG, LEV M: *Anatomic variations in underdeveloped right ventricle related to tricuspid atresia and stenosis*. J Thorac Cardiovasc Surg 1976; 72: 383-400.
4. DIOGENES TCP, ATIK E, AIELLO VD: *Common arterial trunk associated with absence of right atrioventricular connection*. Int J Cardiol 1977; 17: 329-332.
5. RAO PS, LEVY JM, NIKICICZ E, GILBERT-BARNES EF: *Tricuspid atresia: Association with persistent truncus arteriosus*. Am Heart J 1991; 122: 829-835.
6. SHARMA D, MEHTA AB, BHARATI S, LEV M: *Tricuspid atresia with persistent truncus arteriosus*. Chest 1981; 79: 363-365.
7. SREERAM N, ALVARADO O, PEART I: *Tricuspid atresia with common arterial trunk: surgical palliation in a neonate*. Int J Cardiol 1991; 32: 251-253.
8. WANG JN, WU MH, WANG JK, LUE HC: *Tricuspid atresia with persistent truncus arteriosus*. J Formos Med Assoc 1999; 98: 290-291.
9. MALEC E, MROCZEK T, PAJAK J, KORDON Z: *Operative treatment of truncus arteriosus coexisting with tricuspid atresia*. Ann Thorac Surg 2000; 69: 278-280.
10. DI GEORGE AM: *Discussion on a new concept of the cellular basis of immunology*. J Pediatr 1965; 67: 907-908.
11. CONLEY ME, BECKWITH JB, MANCER JFK: *The spectrum of DiGeorge syndrome*. J Pediatr 1979; 94: 883-890.
12. MOMMA K, ANDO M, MATSUOKA R: *Truncus arteriosus communis associated with chromosome 22q11 deletion*. J Am Coll Cardiol 1977; 30: 1067-1071.