

Review

doi: 10.35366/113618

## Complex clubfoot: my 5 tips for appropriate evaluation and treatment with the Ponseti method

*Pie equinovaro complejo: mis 5 consejos para una evaluación y tratamiento adecuados con el método de Ponseti*

Masquijo J,\* Arana E‡

Sanatorio Allende, Córdoba, Argentina.

**ABSTRACT.** Complex clubfoot is a term used to describe a subset of patients that received previous treatment, and have distinctive anatomical features: severe equinus, with short first metatarsal, hyperextended big toe, severe plantar flexion of all metatarsals and deep folds through the sole of the foot and above the heel. Most complex clubfeet appear to be idiopathic and is usually associated with a poor casting technique. Complex clubfoot requires an early recognition and an adjustment of the casting protocol using the four finger Ponseti technique. This article gives the treating physician a general overview of the evaluation, treatment, and outcomes of complex clubfoot with the Ponseti method.

**Keywords:** complex clubfoot, Ponseti method, deformity, children.

**RESUMEN.** El pie equinovaro complejo es un término utilizado para describir un subconjunto de pacientes que recibieron tratamiento previo y tienen características anatómicas distintivas: equino severo, con primer metatarsiano corto, dedo gordo hiperextendido, flexión plantar severa de todos los metatarsianos y pliegues profundos en la planta del pie y por encima del talón. Los pies equinovaros más complejos parecen ser idiopáticos y generalmente se asocian con una mala técnica de yeso. El pie equinovaro complejo requiere un reconocimiento temprano y un ajuste del protocolo de yeso utilizando la técnica de Ponseti de cuatro dedos. Este artículo le brinda al médico tratante una descripción general de la evaluación, el tratamiento y los resultados del pie equinovaro complejo con el método Ponseti.

**Palabras clave:** pie equinovaro complejo, método Ponseti, deformidad, niños.

### Introduction

Clubfoot is the most frequent congenital deformity of foot, with an incidence of 0.51 to 2.03 per 1,000 live births.<sup>1</sup> Complex clubfoot is a term used to describe a subset of

patients that have received previous treatment, have typical anatomic characteristics, and are very severe and resistant to manipulation. Regarding occurrence, different series have reported incidence rates ranging from 7 to 17%,<sup>2,3</sup> being boys affected in a larger percentage compared to girls.

### Level of evidence: V

\* Department of Pediatric Orthopedics and Traumatology, Sanatorio Allende. Cordoba, Argentina.

‡ Pediatric Orthopedic Surgery Service. Benemérito Hospital Civil de Guadalajara «Fray Antonio Alcalde». Guadalajara, Mexico.

### Correspondence:

Dr. Javier Masquijo

Department of Pediatric Orthopedics and Traumatology,

Sanatorio Allende, Cordoba, Argentina. Independencia 757, 1<sup>er</sup> piso, Córdoba.

**E-mail:** jmasquijo@gmail.com

*Received: 07-21-2023. Accepted: 08-25-2023.*

**How to cite:** Masquijo J, Arana E. Complex clubfoot: my 5 tips for appropriate evaluation and treatment with the Ponseti method. Acta Ortop Mex. 2023; 37(4): 233-236. <https://dx.doi.org/10.35366/113618>



This subtype of clubfoot is usually associated with a poor plaster casting technique, frequently slipping down the casts or casting a swollen leg. When the long leg cast is not properly molded, it can lead to the foot sliding within the cast, resulting in abnormal forces on the foot. This can cause the calcaneus to be pushed up, putting pressure on the Achilles tendon and further shortening it, leading to a severe equinus condition (*Figure 1*). Externally, this manifests as a deep crease above the heel, along with changes in the outline and shape of the heel. The heel becomes swollen, soft, and appears empty. Additionally, due to the foot's position in the cast, the plantar fascia becomes excessively shortened, causing the metatarsals to be in a plantar flexion position. This results in a deep transverse crease on the bottom of the foot, which can be observed from both the medial and lateral sides. There is also hyperextension of the first toe due to the «windlass mechanism». Furthermore, there may be edema on the dorsum of the foot, caused by compression from the cast and a decrease in venous return.

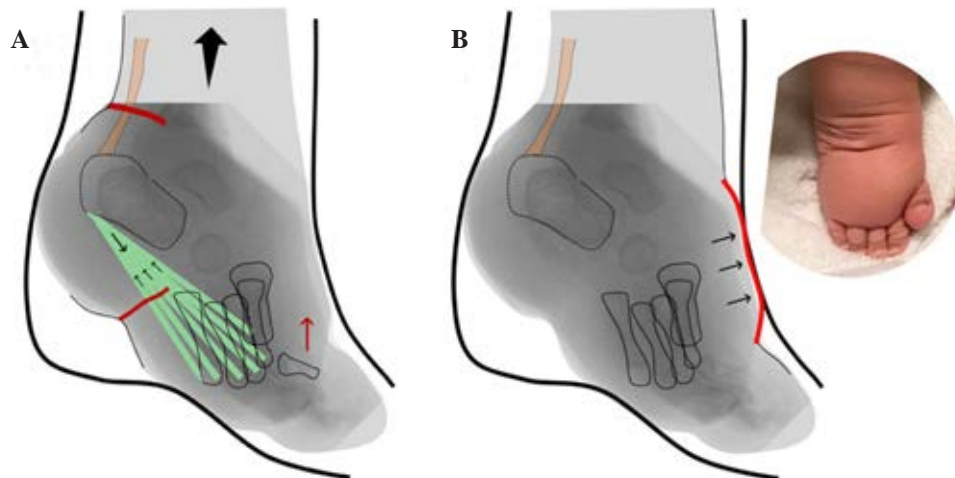
#### Five pearls for evaluation and treatment:

1. Recognize it early!: patients with complex clubfoot exhibit distinctive features that become evident after casting treatment, including severe equinus, a short first metatarsal, hyperextended big toe, severe plantar flexion of all metatarsals, and deep folds through the sole of the foot and above the heel (*Figure 2*). Early identification of complex clubfoot and a modification of the standard protocol, as described by Ponseti,<sup>2</sup> are critical for achieving successful correction.
2. Rule out neurological abnormalities: some authors<sup>4,5</sup> have suggested a neurological dysfunction of the peroneal

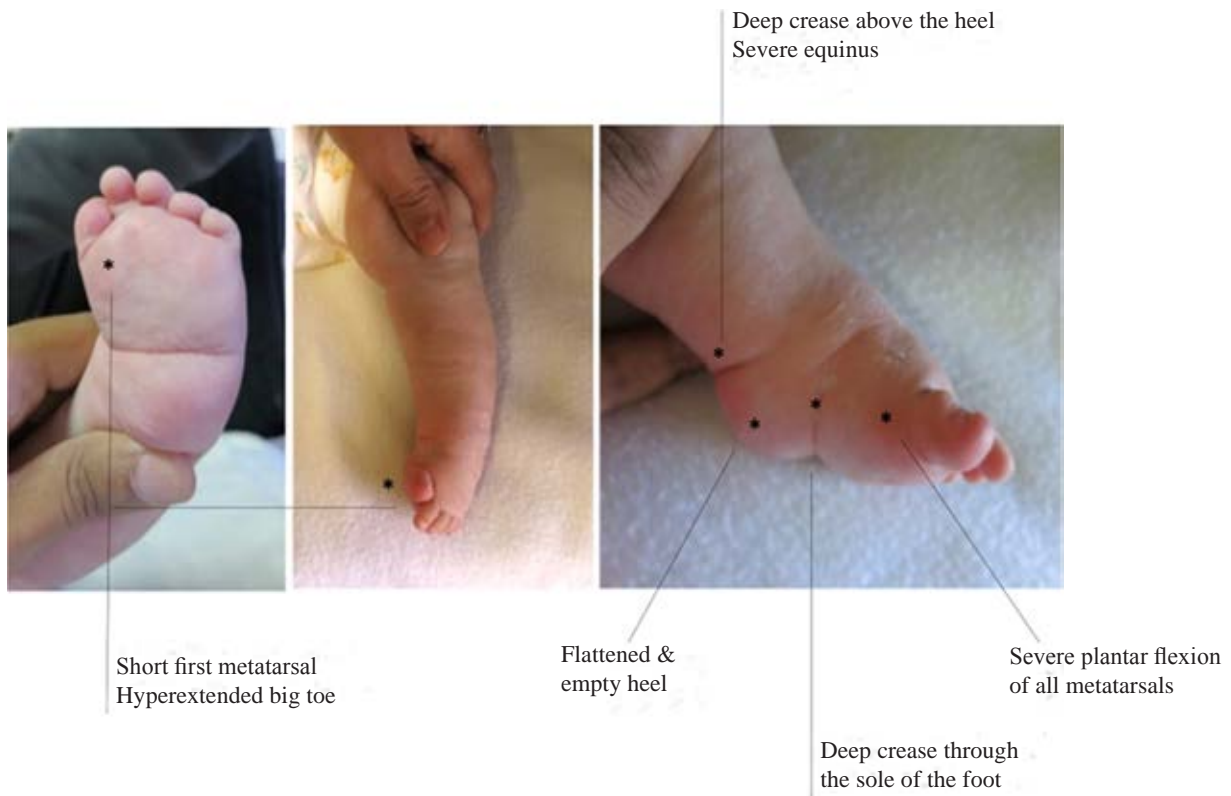
nerve as possibly related to the complex clubfoot. For that reason, a thorough neurological workup should be done, particularly to rule out abnormalities of the anterior and lateral calf compartments. Absence of active dorsiflexion of the ankle, no active eversion, the drop toe sign, and calf atrophy are indicators of neurogenic clubfoot.

Atypical and complex clubfoot has been used as an interchangeable term in the literature. Even though the anatomical features and the initial approach is similar (both are addressed with a similar manipulation and casting technique), they are different entities and may require different bracing protocols. Most of the CCF presents after the typical idiopathic clubfoot slips in the cast. On the other hand, atypical clubfeet, are in a large number neurogenic. When we evaluate a patient with prior casting treatment, it is difficult to differentiate between the two entities.

3. Apply the four finger Ponseti protocol for manipulation and casting: if the baby present foot edema, erythema, and irritability it is convenient to wait a few weeks until the swelling has gone down, before starting manipulation and casting. Cavus deformity and hindfoot equinus must be corrected simultaneously by grasping the foot by the ankle with both hands while pushing with the two thumbs under the head of the metatarsals while an assistant immobilizes the knee in 110° of flexion («four finger technique»). The cast is well molded in the sole, taking special attention of molding the anterior aspect of tibia to prevent anterior tibial bowing, with careful molding of popliteal fossa. Toes must be aligned and with plantar support. Foot abduction is gradually corrected in the subsequent casts, and should not overcome 40°, and talar



**Figure 1:** Etiology of complex clubfoot. **A)** The diagram illustrates the consequences of foot sliding within the cast, resulting in the upward displacement of the calcaneus. This displacement leads to compression of the Achilles tendon and the development of a severe equinus condition. One external symptom of this condition is the presence of a deep crease above the heel. Additionally, the shape of the heel undergoes changes, including significant swelling, flattening, and an empty appearance. The position of the foot within the cast causes excessive shortening of the plantar fascia, leading to a severe cavus deformity of the metatarsals. A visible external manifestation of this is a deep transverse crease on the bottom of the foot, along with hyperextension of the first toe due to the «windlass mechanism». **B)** In some cases, patients may experience edema on the dorsum of the foot as a result of the cast's compression and reduced venous return.



**Figure 2:** Anatomic features of complex clubfoot.

head coverage should be complete. Achilles tenotomy should be performed after correction of the metatarsals plantarflexion and prior to placement of the last cast. Some surgeons would argue that an early tenotomy is a good strategy to avoid cast slipping. It's our experience that cast slipping can be avoided following the principles of good casting in CCF (minimal padding, well-molded cast and knee hyperflexion). Also, a more effective stretch of the plantar fascia, and a better reduction of the cavus can be obtained using the Achilles' tendon as a counterforce.

4. Train parents for successful bracing: bracing is started as soon as the final cast is removed to prevent relapses. Abduction brace is placed with the shoes in 30° to 40° of abduction. Later, when the foot takes proper shape, the abduction can be increased gradually every few weeks to finally reach 60-70°. Braces must be worn 23 hours/day for three months following treatment and then 12-14 hours/day (while the child is sleeping) until the child is five years-old.
5. Be prepared for relapses: although the Ponseti method is very effective for initial correction, patients with complex clubfoot are associated with a higher risk of relapse. Multiple authors reported a recurrence rate that ranges from 14 to 55%.<sup>2,6,7,8</sup> A recent Latin-American multicenter study,<sup>8</sup> showed that initial correction using the Ponseti four finger technique was very effective (98% of cases) with a mean of five casts. However, almost one

out of three patients had a relapse (29.8%). This subgroup required a significantly higher number of casts to achieve initial correction compared to the non-relapse group (6 casts, IQR5, min-max 1-12 versus 4 casts IQR4, min-max 1-13,  $p < 0.001$ ). Treatment of recurrences depends on type of relapse and its severity. Regardless of age, the treatment should start with re-casting. Some patients may require repeating tenotomy of the Achilles tendon, and/or anterior tibialis tendon transfer (ATTT). Surgical release is rarely needed.

## Results

The Ponseti four finger technique is an effective first-line treatment for complex idiopathic clubfoot. However, such children will often require more casts and a higher risk of relapse requiring surgical procedures. *Table 1* shows a summary of recent articles evaluating CCF. Complications related to manipulation and casting range in the literature from 0 to 44%, and include erythema, swelling, allergic contact dermatitis, sores, rocker-bottom deformity, midfoot hyperabduction, and cast slippage.<sup>16</sup>

## Conclusion

Complex clubfeet may be recognized by characteristic anatomic features. Proper casting using the «four finger technique» avoiding hyperabduction, can achieve a high

Table 1: Summary of recent articles evaluating complex clubfoot.

Author (year)	Patients (feet)	Mean age in months	Males/females	TAT	Mean number of casts required for correction	Soft tissue procedures	Mean Pirani pre-treatment	Mean Pirani post-treatment	Complications	Relapse	Follow-up in months
Ponseti et al. (2006) <sup>2</sup>	50 (75)	3 (2.2)	31/19	100% (75)	5 (2.25)	2/50	NR	NR	22%	14% (7/50)	NR
Yoshioka et al. (2010) <sup>5</sup>	8 (10)	17.7 (11.25)	5/3	100% (10)	5 (1.75)	1/8	NR	NR	0%	37.5% (3/8)	15.8 (5)
Gupta et al. (2015) <sup>9</sup>	16 (16)	3.2 (1)	10/6	100% (16)	7 (1.25)	0/16	NR	NR	NR	0% (0/16)	24(6)
Matar et al. (2017) <sup>6</sup>	11 (17)	1.2 (2)	9/2	100% (17)	7 (1.25)	6/17	5.5 (0.38)	NR	NR	53% (9/17)	84 (24)
Elseddik et al. (2018) <sup>10</sup>	19 (28)	1.25 (2.3)	14/5	100% (28)	5.6 (1)	0/28	6 (0)	0 (0.12)	21%	0% (0/28)	7.5 (1.4)
Dragoni et al. (2018) <sup>7</sup>	9 (9)	NR	NR	100% (9)	6 (1)	5/9	NR	NR	NR	56% (5/9)	86.4 (10.8)
Mandlecha et al. (2019) <sup>11</sup>	16 (27)	4.77	13/3	100% (27)	7.44 (1)	NR	5.6 (0.38)	0.06	33%	67% (3/27)	14.8 (4)
Duman et al. (2020) <sup>12</sup>	21 (32)	4 (2.5)	NR	93.8% (30)	5 (1.3)	6/32	5.1 (0.5)	NR	NR	12.5% (4/32)	56 (30)
Allende et al. (2020) <sup>8</sup>	79 (124)	7 (15)	44/35	96% (119)	5 (1.3)	2/124	6 (1)	0.5 (0.5)	5.6%	29.8% (37/124)	49 (30)
Agarwal et al. (2020) <sup>13</sup>	11 (17)	6.7	8/3	NR	7	NR	5.8	0.2	NR	24% (4/17)	22.6
Bozkurt et al. (2021) <sup>14</sup>	11 (16)	2 (1.66)	10/1	100% (16)	7 (0.75)	NR	5.2 (0.5)	0.4 (0.4)	44%	27% (3/11)	13.3 (1.5)
Loose et al. (2023) <sup>15</sup>	13 (22)	6.1	6/10	NR	6.1	16/27	NR	NR	NR	66.6% (18/27)	138

TAT = tendoachilles tenotomy, NR = not reported.

rate of initial correction. Parents advice on using a foot abduction brace is key to decrease the risk of relapses. Despite adherent bracing, in general, complex clubfeet are associated with a higher risk of relapse. Recurrences should be identified early and treated again with casting, repeat tenotomy, ATTT, or rarely, surgical release.

References

- Smythe T, Kuper H, Macleod D, Foster A, Lavy C. Birth prevalence of congenital talipes equinovarus in low- and middle-income countries: a systematic review and meta-analysis. *Trop Med Int Health*. 2017; 22(3): 269-85. doi: 10.1111/tmi.12833.
- Ponseti IV, Zhivkov M, Davis N, Sinclair M, Dobbs MB, Morcuende JA. Treatment of the complex idiopathic clubfoot. *Clin Orthop Relat Res*. 2006; 451: 171-6.
- van Bosse HJP. Challenging clubfeet: the arthrogryptic clubfoot and the complex clubfoot. *J Child Orthop*. 2019; 13(3): 271-81.
- Edmonds EW, Frick SL. The drop toe sign: an indicator of neurologic impairment in congenital clubfoot. *Clin Orthop Relat Res*. 2009; 467(5): 1238-42.
- Yoshioka S, Huisman NJ, Morcuende JA. Peroneal nerve dysfunction in patients with complex clubfeet. *Iowa Orthop J*. 2010; 30: 24-8.
- Matar HE, Beirne P, Bruce CE, Garg NK. Treatment of complex idiopathic clubfoot using the modified Ponseti method: up to 11 years follow-up. *J Pediatr Orthop B*. 2017; 26(2): 137-42.
- Dragoni M, Gabrielli A, Farsetti P, Bellini D, Maglione P, Ippolito E. Complex iatrogenic clubfoot: is it a real entity? *J Pediatr Orthop B*. 2018; 27(5): 428-34.
- Allende V, Paz M, Sanchez S, Lanfranchi L, Torres-Gomez A, Arana E, et al. Complex clubfoot treatment with Ponseti method: a Latin American multicentric study. *J Pediatr Orthop*. 2020; 40(5): 241-5.
- Gupta A, Hakak A, Singh R, Ghani A, Ahmad J. Atypical clubfoot: early identification and treatment by modification of standard Ponseti technique. *Int J Adv Res*. 2015; 3: 1229-34.
- Elseddik HM, Helal MM, Kholeif MM, Sherif MM. Modified Ponseti manipulation and casting technique for treatment of atypical clubfoot. *Egypt Orthop J*. 2018; 55: 123-7.
- Mandlecha P, Kanojia RK, Champawat VS, Kumar A. Evaluation of modified Ponseti technique in treatment of complex clubfeet. *J Clin Orthop Trauma*. 2019; 10(3): 599-608.
- Duman S, Camurcu Y, Cobden A, Ucpunar H, Karahan N, Bursali A. Clinical outcomes of iatrogenic complex clubfoot treated with modified Ponseti method. *Int Orthop*. 2020; 44(9): 1833-40. doi: 10.1007/s00264-020-04529-6.
- Agarwal A, Gupta S, Rastogi P. Hallux length and deep medial crease in complex clubfeet: do they recover? *J Clin Orthop Trauma*. 2020; 11(3): 453-6. doi: 10.1016/j.jcot.2020.03.004.
- Bozkurt C, Sarikaya B, Sipahioglu S, Altay MA, Cetin BV. Using the modified Ponseti method to treat complex clubfoot: early results. *Jt Dis Relat Surg*. 2021; 32(1): 170-6. doi: 10.5606/ehc.2021.77135.
- Loose O, Fernandez Fernandez F, Langendoerfer M, Wirth T, Eberhardt O. Complex, atypical clubfoot: follow-up after up to 16 years reveals a high risk of relapse but good functional and radiological outcomes. *Arch Orthop Trauma Surg*. 2023; 143(10): 6097-104. doi: 10.1007/s00402-023-04840-y.
- Rangasamy K, Baburaj V, Gopinathan NR, Behera P, Sudesh P, Ravi Subramanian S. Correction results of atypical clubfeet managed with modified Ponseti technique: A meta-analysis of 354 feet. *J Clin Orthop Trauma*. 2022; 31: 101939. doi: 10.1016/j.jcot.2022.101939.

**Conflict of interests:** there are no conflicts of interest.

**Financial support:** this study did not receive any specific grant from funding agencies in the public, commercial, or not-for-profit sectors.