



Pre-syncope and ablation of moderator band premature ventricular contraction

Pre-síncope y ablación de la contracción ventricular prematura con origen en la banda moderadora

William-Fernando Bautista-Vargas*

Keywords:

Ventricular premature complexes, syncope, catheter ablation.

Palabras clave:

Complejos prematuros ventriculares, síncope, ablación por catéter.

ABSTRACT

Introduction: Premature ventricular complex (PVC) is a frequent diagnostic entity. The underlying cardiac condition is important to establish a prognosis; in the majority of the cases with normal heart, PVCs have a good prognosis; nevertheless, there is a specific morphology of PVC related to serious cardiac issues. The moderator band (MB) PVCs are one of these, described in a normal heart condition; however, MB- PVC can lead to ventricular tachycardia, ventricular fibrillation, or even sudden cardiac death. **Material and methods:** The case of a 25-year-old female patient with very symptomatic, precordial palpitations is presented with a history of presyncope. The workflow showed a normal transthoracic echocardiogram, normal cardiac MRI, and evidence of bigeminy cardiac rhythm even an unstable ventricular tachycardia induction in an electrophysiology study. She was taken to ablation therapy, PVCs from the moderator band were found with the highest activation of -52 ms, the use of intracardiac echocardiogram, and successful ablation in an uncommon PVC location is reported. **Results:** The radiofrequency ablation therapy with 35 watts and 42 °C at the highest activation point on the lateral aspect of moderator band (MB) was successful therapy with the induction of ventricular tachycardia during the application of radiofrequency as a result finish of PVCs. **Conclusions:** In patients with pre-syncope, syncope, and even aborted sudden cardiac death secondary to ventricular tachycardia or ventricular fibrillation premature ventricular complexes should be addressed with an invasive strategy as RF ablation therapy with the aim of finish a trigger condition. The moderator band is considered an arrhythmogenic structure, PVCs coming from a MB should be addressed as potential death risk and invasive therapy should be considered earlier than antiarrhythmic drugs.

RESUMEN

Introducción: El complejo ventricular prematuro (CVP) es una entidad de diagnóstico frecuente. La condición cardíaca subyacente es importante para establecer un pronóstico; en la mayoría de los casos con un corazón normal, los CVP tienen un buen pronóstico; sin embargo, existe una morfología específica de éstos relacionada con problemas cardíacos graves. Los CVP de la Banda Moderadora (MB) son uno de éstos, descritos en una condición cardíaca normal; sin embargo, los CVP de la Banda Moderadora pueden llevar a una taquicardia ventricular, fibrilación ventricular o, incluso, muerte súbita cardíaca. **Material y métodos:** Paciente de 25 años con palpitaciones precordiales muy sintomáticas se presenta con un historial de presíncope. El flujo de trabajo mostró un ecocardiograma transtorácico normal, una resonancia magnética cardíaca normal y evidencia de un ritmo cardíaco bigémico; incluso una inducción de taquicardia ventricular inestable en un estudio electrofisiológico. Se llevó a terapia de ablación, se encontraron CVP de la banda moderadora con la activación más alta de -52ms, el uso de ecocardiograma intracardiaco, y se informa de una ablación exitosa en un lugar poco común de CVP. **Resultados:** La terapia de ablación por radiofrecuencia con 35 watts y 42°C en el punto de activación más alto en el aspecto lateral de la banda moderadora (BM) fue una terapia exitosa con la inducción de taquicardia ventricular durante la aplicación de la radiofrecuencia como resultado del acabado de los CVP. **Conclusiones:** En los pacientes con muerte cardíaca súbita pre-síncope, síncope e incluso abortada secundaria a taquicardia ventricular o fibrilación ventricular, los complejos ventriculares prematuros deben ser abordados con una estrategia invasiva como la terapia de ablación por radiofrecuencia, con el objetivo de terminar con una condición desencadenante. La banda moderadora se considera una estructura arritmogénica, los CVP provenientes de una BM deben ser abordados como un riesgo potencial de muerte y la terapia invasiva debe ser considerada antes que los medicamentos antiarrítmicos.

* Head of Department of Electrophysiology. St. Sophia Hospital. Manizales, Caldas, Colombia.

Received:
09/06/2020

Accepted:
16/10/2020

How to cite: Bautista-Vargas William-Fernando. Pre-syncope and ablation of moderator band premature ventricular contraction. Cardiovasc Metab Sci. 2020; 31 (4): 131-136. <https://dx.doi.org/10.35366/97545>



INTRODUCTION

The prevalence of premature ventricular complex (PVC) is determinate by a diagnostic method. Nowadays more people are been using a cardiac monitoring wrist for sports or lazy activities, and it is common to hear about PVC in general populations, it seems that in a few hours of using a monitoring device as a rule almost everyone will have a PVC, not specific data have been published regarding the prevalence of wrist monitoring device.¹ Other modalities are reported: in a study of 122,043 subjects using a conventional electrocardiogram (ECG) for about 48 seconds the prevalence of PVC was reported in 0.8%.² In another study using a 2 minutes ECG monitoring in 13,456 subjects with no history of heart failure and no coronary disease, it is reported a prevalence of 5.5% of PVC.³

The symptoms, PVC burden (percentage in a 24 hours Holter), and the presence of structural heart disease are important information to consider to bring the right treatment.¹ A broad symptom can be present from the skyped precordial chest palpitations to ventricular tachycardia even ventricular fibrillation and sudden cardiac death. As a handy approach, the PVC burden in a 24 hours Holter (10% or more) can be used as an indication to proceed to further therapy with an invasive strategy if there is a cardiomyopathy risk or monitoring medication treatment if the PVC burden is not significant.⁴ There are different tools to figure out if there is or not a normal heart; the ECG brings the information of underline diseases, the

echocardiogram, and more recently the cardiac MRI are useful tools to clarify further conditions; even though the structural heart disease has a hard impact into the prognosis, there is on the contrary PVC with normal heart related with ventricular tachycardia (VT), Ventricular Fibrillation (VF), even Sudden Cardiac Death (SCD).¹

The moderator band premature ventricular complex is a potentially dangerous entity, even with a low PVC burden can lead to VT, VF, or SCD in which cases the prevalence is reported up to 2.5%;^{5,6} nonetheless, there are no data in the general population, further investigation is needed to clarify the epidemiological data.

CASE PRESENTATION

A 25-year-old lady presented to the emergency room complained of precordial palpitations skipped beats like; related to pre-syncope feeling but nor loss of consciousness. Despite she was on metoprolol 50 mg bid and propafenone 150 mg bid, her symptoms were uncontrolled. In the last year, she was admitted several times to the emergency room in a different institution because of pre-syncope episodes, and even had an EP study that concludes unstable ventricular tachycardia which was not able to be ablated due to patient due to the instability of the patient hemodynamic and was planned to implant an implantable loop recorder, and keep on medication. During the follow up she was transferred to our clinic and complained of developing much more severe symptoms with ventricular bigeminy rhythm even with a short coupling interval, so it was planned to

Figure 1:

A) A twelve ECG showing a clinical premature ventricular complex (red rectangle).
B) Implantable cardiac monitor trace showing a bigeminy rhythm.

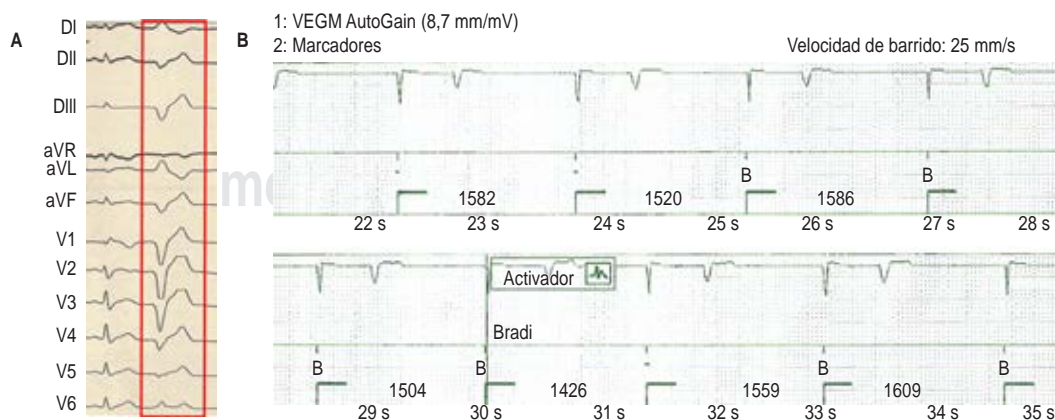
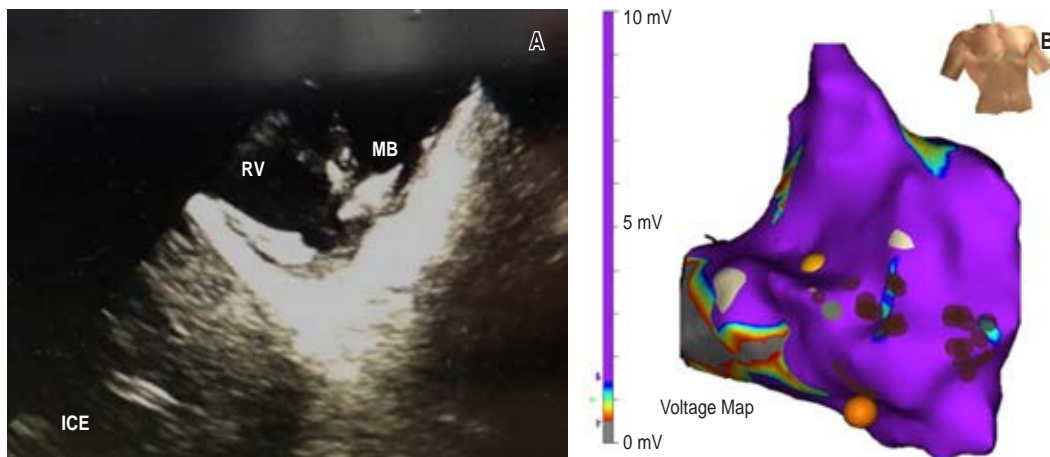


Figure 2:

- A)** Intracardiac echocardiogram (ICE) of the right ventricle (RV) showing a moderator band (MB).
- B)** Voltage map scale (0.5-1.5 mv) showing a normal voltage map.



hospitalize the patient since the medication is not effective.

The electrocardiogram showed ventricular bigeminy, with narrow ventricular premature contractions that are negative in DII, DIII, aVF, aVR, positive in aVL, DI, and V1 with a late precordial transition at V6 (Figure 1). She also had a normal transthoracic echocardiogram, there was no late enhancement in the cardiac MRI, even a normal coronary angiogram. Finally, the patient was taken for an electrophysiology study since she was symptomatic and there was no improvement of her condition on medication.

All medications were discontinued five half-lives, and on the day of the procedure she was in a fasting state, she was taken to Electrophysiology Laboratory with a bigeminy rhythm. Bilateral femoral groin accesses were performed, then a coronary sinus catheter was advanced, an intracardiac echocardiogram probe was used and a bidirectional irrigated catheter, D-F catheter, and Duo-Decapolar catheter were used too. During intracardiac echocardiogram visualization, it was noted a hyper-refringent on the moderator band, then the 3D mapping using the Ensite system (St. Jude Medical, St. Paul, Mn, USA) was performed. During the voltage map, there was no scar related noted (Figure 2) and during the activation map we found a -52 ms activation at the inferior part of the moderator band, then ablation was performed with 35 watts and 42 °C lead to a rapid, stable ventricular tachycardia that was terminated immediately during ablation and disappearance of the PVCs, and as a result, we decided to

apply consolidation points of ablation on that area, with a good outcome. At the end of the procedure, the patient was on sinus rhythm and the implantable loop recorder interrogation during the follow-up did not show any ventricular premature contractions (Figure 3).

DISCUSSION

The moderator band first described as a structure to protect the right ventricle from distention,⁷ goes from the lateral free wall to the septum, it is a muscle structure that courses inferiorly from the right ventricular septum to the base of the anterior papillary muscle of the tricuspid valve,^{8,9} and it is histologically composed by a complex sheaths structure as well as myocardium and more density of specialized Purkinje cells, than the rest of the right ventricle,¹⁰ considered as an important structure because contains a right atrioventricular bundle. Loukas and col. in a morphological study have been classified into five different types from a very thick muscular structure to the absence of the moderator band, they described a mean of the thickness of 4.5 ± 1.8 mm and mean of length of 16.23 ± 2.3 mm.¹¹ The arterial irrigation of the moderator band is from branches of the left coronary system can be found from the second anterior septal artery up to 72% of the cases, 18% from the first anterior septal artery, and 7% from the third anterior septal artery.⁸

The moderator band is considered as a source of potentially fatal arrhythmias as ventricular tachycardia or ventricular fibrillation.¹²

The right band moderator PVC is a rare entity, the prevalence is estimated at 2.5%; however, could be more because the patients who died as a result of this arrhythmia are not counted in the clinical studies; the concern of this kind of arrhythmia is that can lead to ventricular fibrillation and eventually death if there is a delay in the treatment.⁶

The PVC from MB has a LBBB morphology with a left superior axis, and late transition typically from V4 and forward; moreover it can be different if the heart anatomy has congenital variations as it was described by Yasumoto in a patient with corrected transposition of great arteries, where the morphology of PVC was RBBB like.^{13,14}

Treatment of moderator band PVC could be tricky, typically the antiarrhythmic drugs do not work very well because high doses are required and the chance of secondary effects are more likely to be present,¹⁵ with no guarantee of total PVC suppression, as a result, invasive strategy with catheter ablation could be considered as a first option.¹⁶

The ablation is an effective strategy to treat a moderator band premature ventricle contractions, the 3D mapping and intracardiac

echocardiogram are used not only as helping tools to ensure a good definition and contact between catheters and tissue but also to improve ablation lesion and effectiveness and safeness of therapy.⁶

Mapping PVC from MB could be an issue, therefore some strategies should be considered to increase the chance of success as medication drips used during mapping a PVC as isoproterenol or dobutamine iv, pacing during mapping to induce PVC, pace mapping approaches, even using multipolar catheters as Pentaray (Biosense Webster, Diamond Bar, California), to collect as many activation points as you can on one touch.¹⁷

The moderator band contains Purkinje system cells is consider a potentially arrhythmogenic structure, PVC from this structure can lead to a ventricular fibrillation; ablation can be a real challenge to a electrophysiologist;¹⁸ even though, there are several aspects to consider: first the best target is difficult to achieve described as the identification of preceding Purkinje potential, pre ventricular activation, concordant morphology with pace mapping; second: stability is difficult to achieve in this structure, some strategies are been proposed:

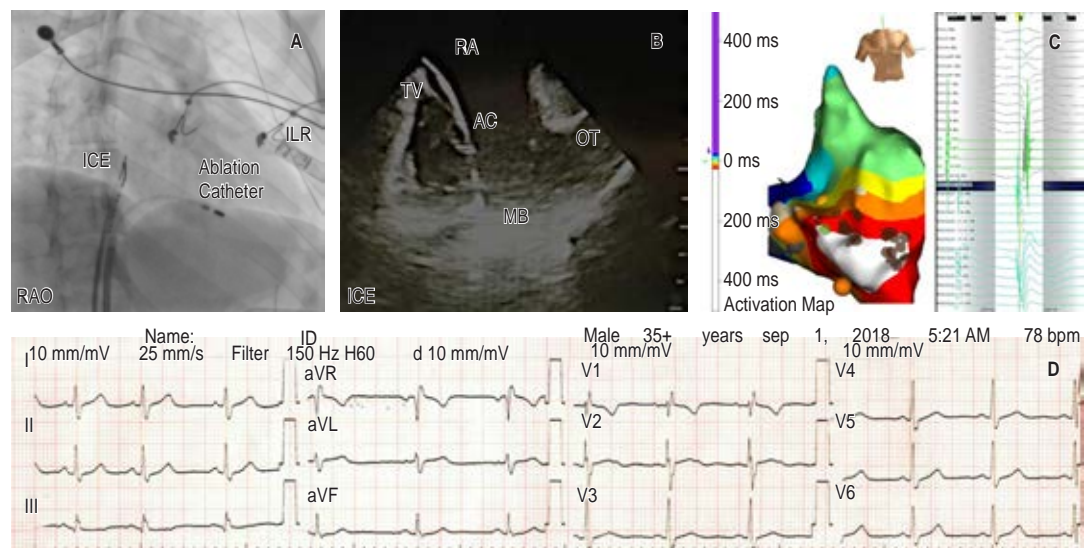


Figure 3: **A)** Right anterior oblique fluoroscopic projection (RAO), showing ablation catheter (AC) at the moderator band (MB). **B)** Intracardiac echocardiogram (ICE) showing the ablation catheter. **C)** Activation map showing the point with the highest precocity -54 ms. **D)** First day ECG with sinus rhythm without premature ventricular contractions (PVC) ILR: implantable loop recorder (ICE), right atrium (RA), tricuspid valve (TV), outflow tract (OT).

using a tridimensional mapping, intracardiac echocardiogram, even cryo catheters to freeze de area,¹⁹ or a strategy who includes: a 3D mapping, ICE, radiofrequency and 23 mm balloon to cryoablation (freezing up to 4 minutes up to -47 °C) has been reported in the setting of a patient with already two failed procedures with successful results,²⁰ at last but not less the ablation with RF or Cryo could be trigger VF or VT, as a destruction of conduction cells during applications.¹⁹

The percentages of the patients who might need a second procedure have been reported up to 60%; and the possible reasons to explain failed procedures or turn an early successful ablation into a fail therapy with increasing of PVC burden are: poor tissue contact with ablation catheter, lack of stability, insufficient deep lesions during ablation, and change of PVC exit (as a result of ablation points); though, a failed procedure can be dangerous to the patient if the clinic is syncope or even ventricular tachycardia or ventricular fibrillation.⁶

CONCLUSIONS

Nowadays the diagnosis of a premature ventricular complex is more common; even though, some specific PVC morphologies should have a more careful follow-up, because of the direct association with ventricular tachycardia, ventricular fibrillation, or even sudden cardiac death, especially the majority of these PVCs are not even symptomatic. The moderator band PVCs are a potentially risky entity and typically presented in a normal heart; moreover, further evaluation is always needed. Ablation therapy should be considered as a first therapy even though there is not a significant PVC burden in patients with a history of pre-syncope, syncope, or severe symptomatic episodes not controlled with antiarrhythmic drugs.

REFERENCES

- Marcus GM. Evaluation and management of premature ventricular complexes. *Circulation*. 2020; 141 (17): 1404-1418.
- Hiss RC, Lamb LE. Electrocardiographic findings in 122,043 individuals. *Circulation*. 1962; 25: 947-961.
- Agarwal SK, Simpson RJ Jr, Rautaharju P, Alonso A, Shahar E, Massing M et al. Relation of ventricular premature complexes to heart failure (from the Atherosclerosis Risk In Communities [ARIC] Study). *Am J Cardiol*. 2012; 109 (1): 105-109.
- Bogun F. Premature ventricular complexes and premature ventricular complex induced cardiomyopathy. *Curr Probl Cardiol*. 2015; 40 (9): 379-422.
- Li YQ, Wang YX, Que DD, Shao J, Song XD, Yang PZ. Successful ablation of moderator band-originated ventricular tachycardia at its ventricle insertion sites. *Chin Med J (Engl)*. 2018; 131 (11): 1371-1372.
- Russo AM. PVCs arising from the moderator band: An under-recognized trigger for idiopathic VF? *Heart Rhythm*. 2015; 12 (1): 76-77.
- Power JH. *Anatomy of the arteries of the human body*. Philadelphia: J.B. Lippincott and Co.; 1862. pp. 37-41.
- Reig J, Albertí N, Petit M. Arterial vascularization of the human moderator band: An analysis of this structure's role as a collateral circulation route. *Clin Anat*. 2000; 13 (4): 244-250.
- Galea N, Carbone I, Cannata D, Cannavale G, Conti B, Galea R et al. Right ventricular cardiovascular magnetic resonance imaging: normal anatomy and spectrum of pathological findings. *Insights Imaging*. 2013; 4 (2): 213-223.
- De Almeida MC, Stephenson RS, Anderson RH, Benvenuti LA, Loukas M, Aiello VD. Human subpulmonary infundibulum has an endocardial network of specialized conducting cardiomyocytes. *Heart Rhythm*. 2020; 17 (1): 123-130.
- Loukas M, Klaassen Z, Tubbs RS, Derderian T, Paling DAN, Chow D et al. Anatomical observations of the moderator band. *Clin Anat*. 2010; 23 (4): 443-450.
- Sadek MM, Benhayon D, Sureddi R, Chik W, Santangeli P, Supple GE et al. Idiopathic ventricular arrhythmias originating from the moderator band: Electrocardiographic characteristics and treatment by catheter ablation. *Heart Rhythm*. 2015; 12 (1): 67-75.
- Sadek MM, Marchlinski FE. Ablation of ventricular arrhythmias. *Trends Cardiovasc Med*. 2014; 24 (7): 296-304.
- Yasumoto K, Egami Y, Nakamura H, Matsuhira Y, Yasumura K, Tanaka A et al. Successful ablation for premature ventricular contraction originating from moderator band of morphologic right ventricle in congenitally corrected transposition of great arteries. *J Electrocardiol*. 2019; 56: 106-108.
- Anter E, Buxton AE, Silverstein JR, Josephson ME. Idiopathic ventricular fibrillation originating from the moderator band. *J Cardiovasc Electrophysiol*. 2013; 24 (1): 97-100.
- Cronin EM, Bogun FM, Maury P, Peichl P, Chen M, Namboodiri N et al. 2019 HRS/EHRA/APHRS/LAHS expert consensus statement on catheter ablation of ventricular arrhythmias. *Heart Rhythm*. 2020; 17 (1): e2-154.
- Ho RT, Frisch DR, Greenspon AJ. Idiopathic ventricular fibrillation ablation facilitated by PENTARAY mapping of the moderator band. *JACC Clin Electrophysiol*. 2017; 3 (3): 313-314.
- Singh P, Noheria A. Ablation approaches for ventricular fibrillation. *Curr Treat Options Cardiovasc Med*. 2018; 20 (3): 21.
- Barber M, Chinitz J, John R. Arrhythmias from the right ventricular moderator band: diagnosis and manage-

- ment. *Arrhythmia Electrophysiol Rev.* 2020; 8 (4): 294-299.
20. Chinitz JS, Sedaghat D, Harding M, Darge A, Epstein LM, John R. Adjuvant use of a cryoballoon to facilitate ablation of premature ventricular contraction-triggered ventricular fibrillation originating from the moderator band. *HeartRhythm Case Rep.* 2019; 5 (12): 578-581.

Correspondence to:**William-Fernando Bautista-Vargas**Carrera 23 #65^a-41 Consultorio 904,

ZIP code: 170003, Manizales,

Caldas, Colombia.

Phone: +573125315075

E-mail: Williambautista679@icloud.com

www.medigraphic.org.mx