



Atrophic maxilla rehabilitation with use of «All-on-Four» tilted implants

Rehabilitación de una maxila atrófica con el uso de implantes inclinados «All-on-Four»

Iván Contreras Molina,* Gildardo Contreras Molina,[§] Karla Nunes Teixeira,^{||}
Pamela Candida Aires Ribas de Andrade,^{||} Marco Aurélio Bianchini[¶]

ABSTRACT

Maxillary resorption inflicts limitations to implant placement when using conventional techniques. The concept of «All-on-Four» uses distally inclined implants in edentulous arches; it improves denture support and increases inter-implant distance, providing thus greater stability in the bone with the help of longer implants. For over two decades, different types of therapies have been developed to rehabilitate atrophic or edentulous arches. Obtained results have been of a diverse nature. Among proposed techniques we can count bone graft and maxillary sinus elevation. In order to avoid this type of procedures, a different surgical alternative has been developed: this technique consists on placing four implants, two anterior and two tilted posterior implants, all linked by an infrastructure. The clinical case here presented describes a technique used to restore an atrophic maxilla following the «All-on-Four» concept, with immediate load. The patient was subjected to a one year follow-up and was satisfied with the treatment outcome. To this date, no clinical or radiographic changes have been observed around the dental implants nor have there been prosthetic complications.

Key words: Rehabilitation, atrophic maxilla, All-on-Four.

Palabras clave: Rehabilitación, maxila atrófica, All-on-Four.

RESUMEN

La reabsorción de la maxila presenta limitaciones en la colocación de implantes por medio de la técnica convencional. El concepto de «All-on-Four» sobre la inclinación distal de implantes en arcadas desdentadas mejora el soporte de la prótesis y aumenta la distancia interimplantar, proporcionando una mayor estabilidad en el hueso mediante el uso de implantes más largos. Durante más de dos décadas, diferentes tipos de terapias se han desarrollado en la rehabilitación de arcadas atróficas o edéntulas, lo cual ha traído resultados diversos. Entre las técnicas propuestas están el injerto óseo y el levantamiento de seno maxilar. Para evitar este tipo de procedimientos se desarrolló una alternativa quirúrgica diferente, que consiste en la colocación de cuatro implantes, dos anteriores y dos posteriores, siendo estos últimos inclinados, todos unidos por medio de una infraestructura. Este caso clínico describe una técnica para restaurar una maxila atrófica con el concepto «All-on-Four» con carga inmediata. La paciente ha tenido un seguimiento clínico durante un año y está satisfecha con el resultado del tratamiento. No se han observado cambios clínicos ni radiográficos alrededor de los implantes dentales hasta la fecha, no ha habido complicaciones protésicas.

INTRODUCTION

Fixed, implant-supported dentures in edentulous upper and lower jaws were originally used by placing five to six implants. This was called the Brånemark protocol. In most cases, the maxilla presented moderate to severe resorption, with maxillary sinus pneumatization. This system required reconstructive surgery based on bone grafting which could enable the placement of that number of implants. Brånemark protocol prostheses supported cantilever extensions which protruded distally due to bone unavailability in posterior regions.¹

Predictable results were obtained with the increase in knowledge of bone integration and implant biomechanics. Rehabilitating treatments

involving lesser amounts of implants as well as their inclination were conducted. Placement of four implants, two in the anterior section and two

* MSc, PhD, Visiting Student at the University of Southern California (USC) Dentistry.

[§] DDS, Endodontics Professor, University San Nicolas Hidalgo (Universidad Michoacana de San Nicolás de Hidalgo), Morelia, Mexico.

^{||} MSc, PhD, Department of Dentistry, Federal University of Santa Catarina, Brazil.

[¶] MSc, PhD, Associate Professor, Department of Dentistry, Master and PhD in Implantology, Federal University of Santa Catarina, Brazil.

tilted implants in the posterior section improved anchorage since they used cortical bone from the anterior section of the maxillary sinus and the nasal passage (nostril). This represented an alternative therapy to avoid reconstructive surgery or bone graft procedures. It also represented a less invasive and financially competitive treatment. The so-called surgical technique of tilted implants «All-on-Four» and «All-on-Six» consists of a technique where implants are linked by means of a structure. Tilting of the posterior implants allows the screws to emerge in the region of the second premolars, or first molars, thus decreasing or avoiding cantilever, since, when it is minimized, the denture will be subjected to lesser mechanical stress.² The present clinical report describes a method to restore an atrophic maxilla with the «All-on-Four» technique, using the concept of immediate load.

CLINICAL CASE REPORT

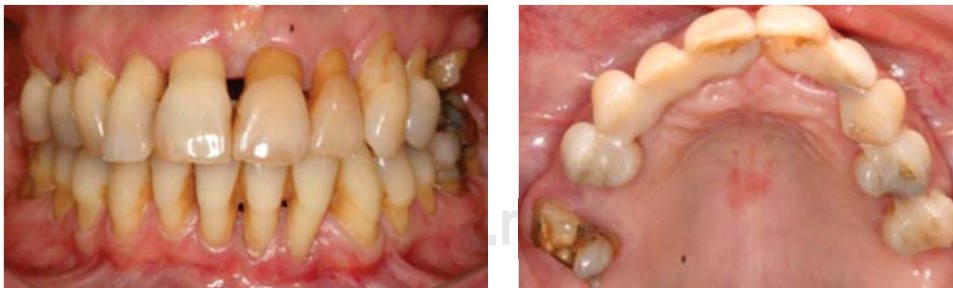59 year old female patient attended the Implantology Clinic at the Dental Implant Study and Research Center (CEPID) at the Federal University Santa Catarina, Brazil. The patient had been previously treated at the University's periodontics clinic, where several treatments had been undertaken in order to preserve to the utmost existing teeth. During her last visit, splinting of all upper and lower teeth had been decided upon, keeping them thus functioning in the last five years. At the follow-up appointment the patient expressed her wish to achieve better aesthetics; clinical examination revealed increase tooth mobility in

the upper jaw. Several possible treatment options were discussed with the patient. The concept of «All-on-Four» therapy was proposed, where the patient would receive four implants in the maxilla, and implants would be immediately loaded with a prosthesis.

Preliminary studies requested were cone beam tomography, panoramic and periapical series of both upper and lower jaws, study models and extra- and intra-oral pictures. With all the aforementioned in hand, treatment planning was undertaken (*Figures 1 to 4*).

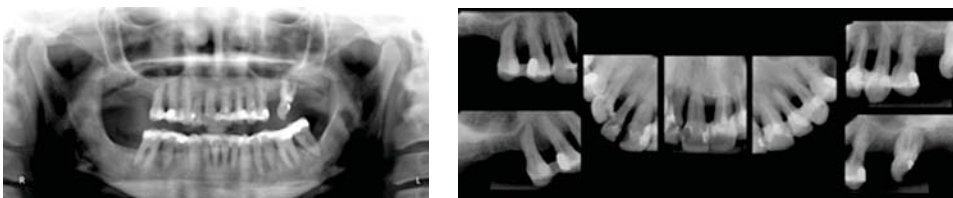Impressions were achieved with alginate (Jeltrate, Dentsply International, New York) in both dental arches. Study models were obtained, and were mounted on a semi-adjustable articulator, according to classical concepts and techniques. Waxing for an immediate full denture was undertaken, and it was replicated in order to obtain a multi-functional surgical guide. All upper teeth were extracted (*Figure 5*) and a muco-periosteal flap was raised at the level of the bone crest, with relaxing incisions in the vestibular section at the level of the molars. A high speed round diamond burr was used to open the maxillary sinus, with external irrigation so as to accurately identify the anterior wall of the maxillary sinus (*Figure 6*).

Once the anterior wall of the sinus was located, surgical sequence for implant placement was undertaken. The two first implants to be placed were those most distally located, with the following measures: 3.75 x 19 mm, after this, the anterior implants were placed, with the following measures 3.75 x 15 mm. Implants used were Cone Morse



Figures 1 and 2.

Initial circumstances of the patient.



Figures 3 and 4.

Periapical and panoramic X-rays.

(Neodent, Curitiba, Brazil). Instant placement was uneventful. Implants exhibited an upper torque of 45 N/cm. Multifunctional guide was used at all times during surgery to ease implant placement with respect to the lower jaw as well as proper tilting of posterior implants (*Figures 7 and 8*).

Frontally placed implants are usually placed in the position of central or lateral incisors. Posterior implants can be placed in second premolar or first molar position creating thus a larger inter-implant distance and a shorter cantilever. Used components were conic mini-pillars, the two posterior implants were angulated at 17°. All components had a 3.5 tape. After component installation a 32 N/cm torque was applied following manufacturer's instructions. Transfers were installed, changing the transfer screw for a short screw, in order to be able to perform the transference with the mouth closed. The flap was closed using Ethicon non resorbable silk suture 4-0 (Johnson and Johnson, USA).

The multifunctional surgical guide was used to achieve the transference impression and record

maxillary-mandibular relationship. Transfers were linked with dental floss, and small increments of Duralay (GC Pattern resin, GO America Inc) resin were added in their midst in order to link them. In this case, inter-implant distance was very large, therefore, implant molds were used to ease bonding and minimize resin contraction. After this, they were linked to the surgical guide (*Figure 9*). Once the guide was in position an inter-occlusal recording was made with Duralay resin. One point in the anterior section and two points in the posterior section were located in occlusion, preserving the same vertical dimension (*Figure 10*). The impression was taken with polyvinyl siloxane material (Express addition, 3M USA) (*Figure 11*). Once the impression was taken, implant analogues were placed into the impression and the working model was obtained.

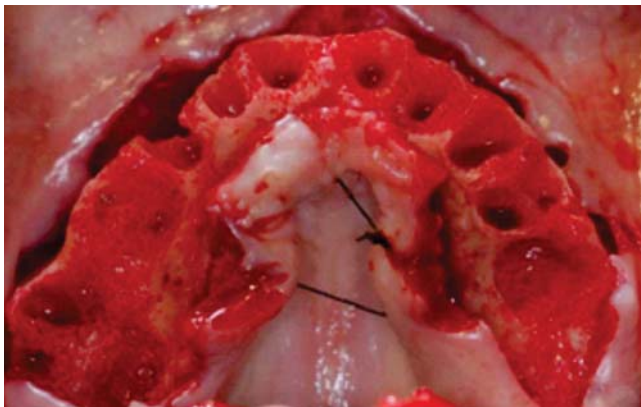


Figure 5. Extraction of all teeth.

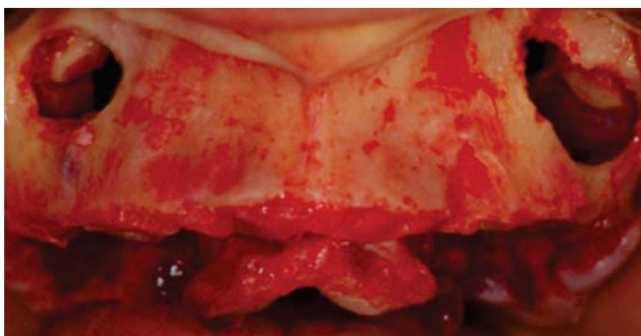


Figure 6. Opening of maxillary sinuses.

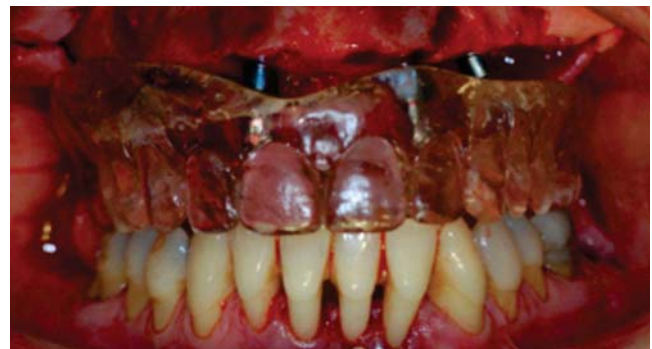

Figure 7. Surgical guide in place, pre-visualizing implant position.

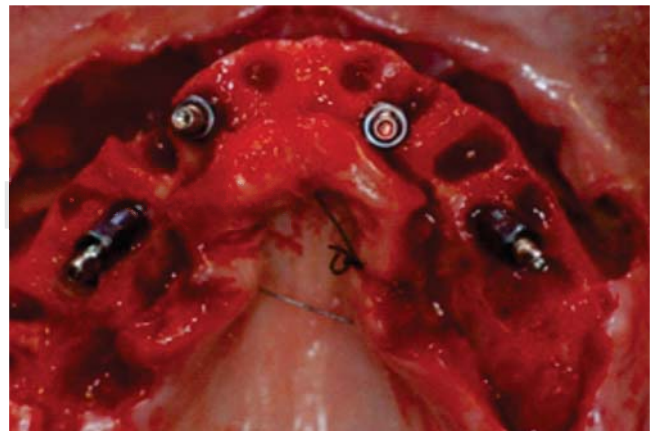


Figure 8. Implants' occlusal view, showing tilting of the two most distally placed implants.

All laboratory steps were followed in the conventional manner. After 24 hours, a test of the teeth in wax was undertaken to double-check all phonetic and esthetic parameters. Once the infrastructure was completed, radiographic and clinical settling were assessed. The structure was then sent to the dental laboratory to be completed. One day after this test, the prosthesis returned to

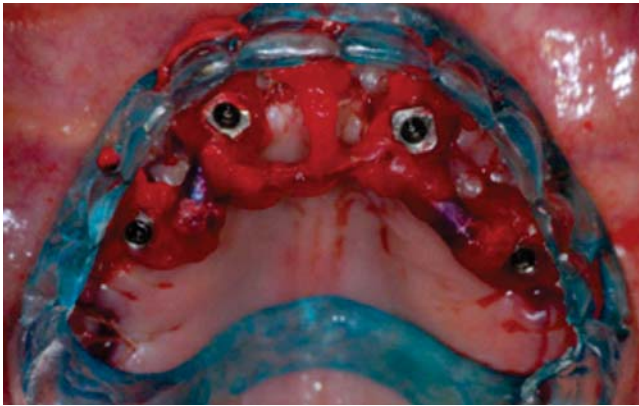

Figure 9. Impression transfers linked to surgical guide.

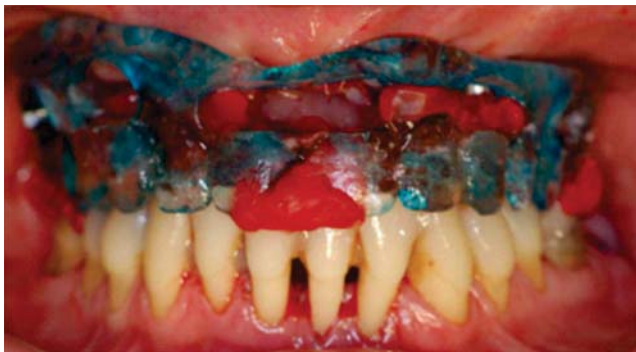

Figure 10. Inter-occlusal record.

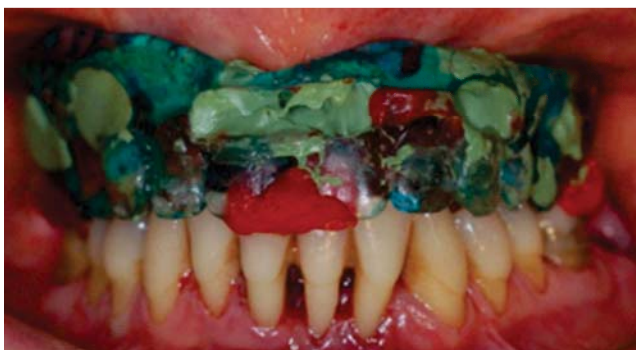

Figure 11. Impression with closed mouth.

the office for occlusal adjustment and installation (*Figures 12 to 15*).

The patient was treated with four dental implants, placed according to the «All-on-Four» technique in the maxilla as well as a fixed prosthesis. The patient was subjected to a 12 month follow-up period, and to this date, is still satisfied with treatment results. No perceptible clinical or radiographic changes were observed around the dental implants. To this date, there have been no complications either in the prosthesis or the implants. The patient is scheduled for a quarterly follow-up, mainly to determine effectiveness of home-administered oral care (*Figures 16 to 18*).

DISCUSSION

The tilted implant technique was introduced to treat atrophic maxillas. These maxillas generally have preserved the alveolar ridge in the region of the pre-maxilla between canines, which is distally limited by

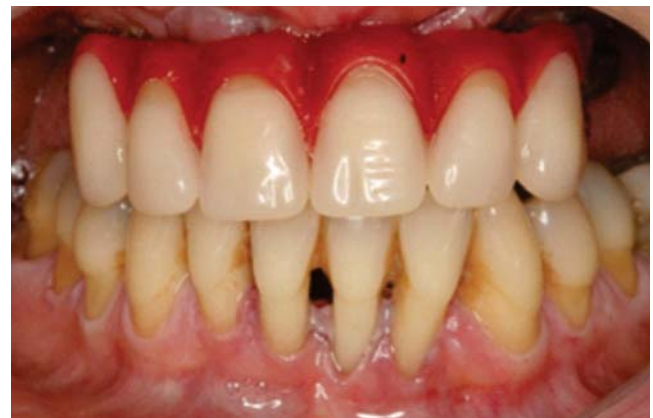

Figure 12. Test of teeth in wax.

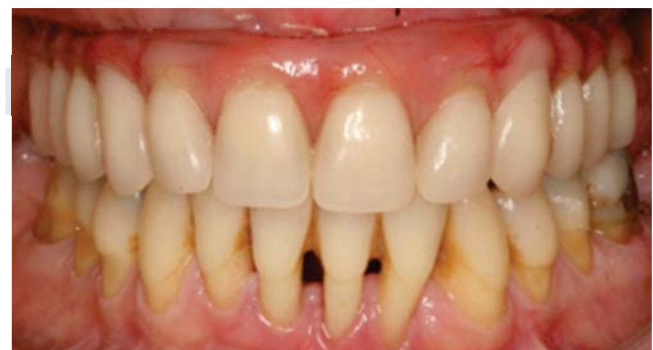
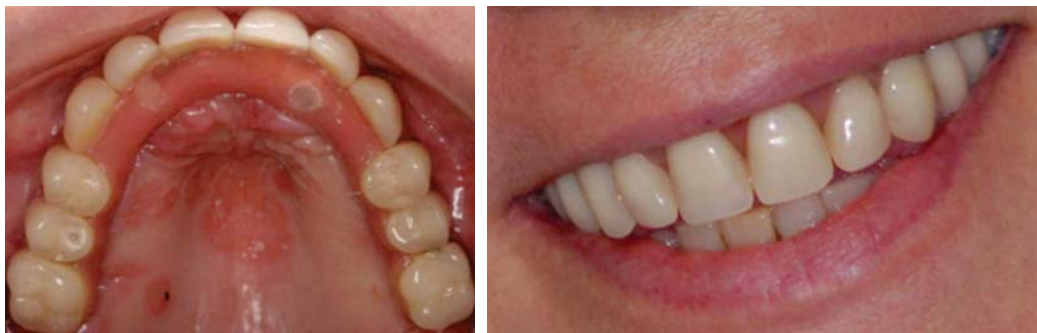
Figure 13. Placement of completed prosthesis.



Figures 14 and 15.

Occlusal view of the prosthesis and patient's smile.

the anterior wall of the maxillary sinus at both sides. Pneumatization of the maxillary sinus might require the following: placement of distally tilted, longer implants, installed areas of greater bone density, screws merging near the region of first molars, improving thus the geometric disposition of the prosthesis/implant ensemble. If the aforementioned technique were not to be used, these regions would receive short implants or even grafts, and this would increase case complexity, as well as treatment time and cost.³⁻⁵

Opposite to what might be desirable, more distally placed implants are responsible for the absorption and dissipation of occlusal forces of greater might. They are shorter due to the sinuses' anatomy.^{6,7} With distally tilted implants the length of the prosthesis supported polygon increases and the cantilever extension decreases.^{5,8}

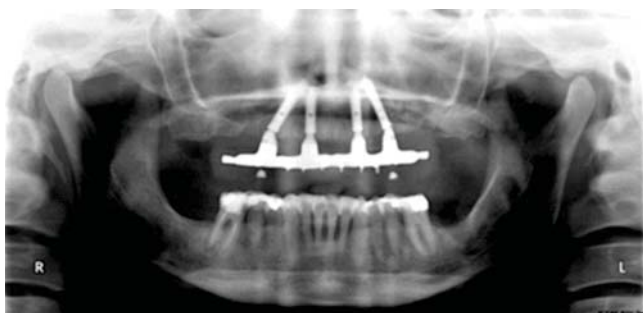
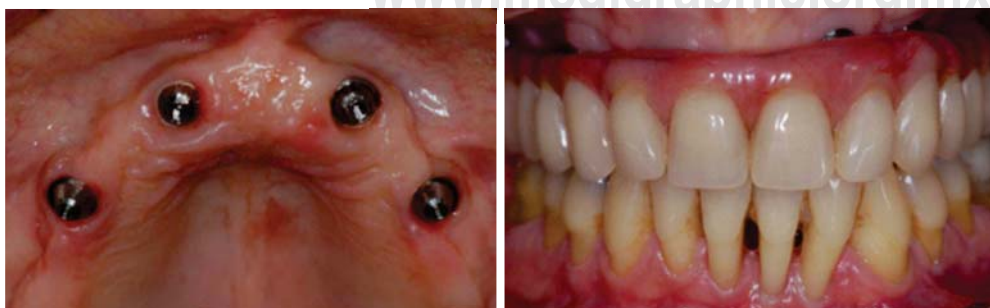
Figure 16. One year post operative X-ray.

According to bio-engineering studies, distally placed implants must be rigidly linked to other implants, so that, upon binding, the geometrical disposition of the outfit implant/prosthesis will be greater, achieving thus a more bio-mechanically favorable system.⁹ A ten-year retrospective study assessed the survival index of prostheses/implants in 156 patients which had been rehabilitated with prosthesis placed on four and six implants. Results revealed the fact that, after ten years, survival index for implants and prostheses was the same for both groups.¹⁰ Dr Maló, in 2003,¹¹ in a retrospective, clinical study, assessed immediate-load protocols with four implants (All-on-Four). In the study, it was concluded that use of four immediate-load implants with fixed prosthesis in the maxilla shows a high survival rate after one year, and that tilting of posterior implants was compatible with survival rate.

Callandriello R et al., in 2005¹² published a prospective study where they assessed rehabilitations in atrophic maxillas with the use of tilted implants and early immediate load. A 96.7% survival rate was reported, and they reached the conclusion that use of this technique in edentulous jaws decreased general treatment time, especially surgery time and represented a lower cost. These factors benefit the patient as well as the clinical operator.

Dr Ferreira et al.,¹³ in 2004 suggested the use of this technique in cases of atrophic maxillas, they



Figures 17 and 18.

Clinical circumstances of the patient one year after prosthesis placement.

suggested that tilting of implants in a posterior-anterior direction allows bi-cortical anchorage in denser bone, allowing thus placement of longer implants. This favors primary stability and use of functional immediate load protocol.

CONCLUSION

Based on reviewed studies, use of tilted implants is recommended in cases of moderate maxillary atrophy. Main advantages of this technique when compared to bone graft or zygomatic implant techniques are lesser surgical morbidity as well as optimal use of the residual alveolar ridge. Placement of implants in a region of denser bone tissue allows for lesser total treatment time, lesser cost and avoidance of multiple surgeries.

REFERENCES

1. Brånemark PI. Osseointegration and its experimental background. *Journal of Prosthetic Dentistry*. 1983; 50 (3): 399-410.
2. Bezerra F, Azoubel E. Alternativas cirúrgicas no tratamento da maxila atrófica. In: Bezerra F, Lenharo A. *Terapia clínica avançada em implantodontia*. São Paulo: Artes Médicas; 2002. p. 159.
3. De Leo C. Carga imediata em implantes osseointegrados inclinados: aumentando a superfície de ancoragem: relato de dois casos. *Odonto Ciencia*. 2002; 17: 231-238.
4. Kahnberg KE, Nystrom E, Bartholdsson L. Combined use of bone grafts and Branemark fixtures in the treatment of severely resorbed maxillary. *International Journal of Oral Maxillofacial Implants*. 1989; 4 (4): 297-304.
5. Falk H, Laurell L, Lundgren D. Occlusal interferences and cantilever joint stress in implant-supported prostheses occluding with complete dentures. *International Journal of Oral Maxillofacial Implants*. 1990; 5 (1): 277-283.
6. Aparicio C, Arevalo X, Ouzzani W, Granados C. A retrospective clinical and radiographic evaluation of tilted implants used in the treatment severely resorbed edentulous maxillary. *Appl Osseointegration Res*. 2003; 1: 17-21.
7. Reiser GM. Implant use in the tuberosity, pterygoid, and palatine region: anatomic and surgical considerations. In: Nevisns M, Melloning JT. *Implant therapy*. Quintessence Books. 1998; 2: 197-207.
8. Benzing UR, Gall H, Weber H. Biomechanical aspects of two different implant-prosthetic concepts for edentulous maxillary. *International Journal of Oral Maxillofacial Implants*. 2004; 35 (6): 188-198.
9. Skalak R, Zhao Y. Similarity of stress distribution in bone for various implant surface roughness heights of similar form. *Clinical Implant Dentistry and Related Research*. 2000; 2 (4): 225-230.
10. Brånemark PI, Svensson B, Van Steenberghe D. Ten-year survival rates of fixed prostheses on four or six implants ad modum Brånemark in full edentulismo. *Clinical Oral Implant Research*. 1995; 6 (4): 227-231.
11. Maló P, Rangert B, Nobre M. «All-on-Four» immediate-function concept with Brånemark system implants for completely edentulous mandibles: a retrospective clinical study. *Clinical Implant Dentistry Related Research*. 2003; (Supp 1): 2-9.
12. Callandriello R, Tomantis M. Simplified treatment of the atrophic posterior maxilla via immediate/early function and tilted implants: a prospective 1-year clinical study. *Clinical Implant Dentistry Related Research*. 2005; (Supp1): 1-12.
13. Ferreira AR, Bezerra JB, De Souza SW, Torres E, Da Rocha BV, Lenharo A. O uso de implantes inclinados com carga imediata funcional na reabilitação da maxila completamente edêntula. *Innovations Journal*. 2004; 6: 33-38.

Mailing address:

Iván Contreras Molina

E-mail: dr.ivancontreras@gmail.com