

Generalities in canine papillomavirus: systematic review of case reports

Guillermo Cano-Verdugo^{1*}

 0000-0002-4905-1939

Gabriela Guadalupe Verdugo-Lizárraga²

 0000-0002-7277-0712

David Emmanuel Gámez-Sánchez²

 0000-0001-7318-9500

¹ Universidad Autónoma de Nuevo León,
Facultad de Odontología,
Monterrey, Nuevo León, México.

² Centro Veterinario AlphaVet,
Mazatlán, Sinaloa, México.

*Corresponding author:

Email address:

guillermocano_verdugo@hotmail.com

Abstract

Canine papillomavirus (CPV) is a common entity in dogs that can be transmitted by direct and indirect contact and cause lesions in various parts of the body. It is the main cause of benign tumors; however, if not detected in time, it is a risk factor for the development of squamous cell carcinoma, documented with high mortality. To clarify demographic generalities, location of lesions, and findings involved in CPV detection, a systematic review of case reports of CPV was performed. The PRISMA statement was followed. Literature was searched in PubMed, DOAJ, and CAB Abstracts from 2011 to date. The articles collected were tabulated in Excel with the variables of interest. A total of 54 articles were obtained from the search, and 11 were included in the review after the screening and selection process. The analysis of the information allowed us to identify that among the case reports there were 4 investigations with male dogs, 2 females and 5 unspecified. Age ranged from 2 to 12 years. The breed with more cases reported was the Labrador retriever and 6 reported cases with neutered patients. Regarding the location of the lesions, the most common was the oral cavity, and the main findings were the need to identify new subtypes of CPV, and the development of lesions at lower CD4 and CD8 lymphocyte counts. Further research, encouragement of veterinary medical personnel, and dissemination of CPV-related literature are needed to make this pathology visible and initiate future public health actions.

Keywords: Systematic review; Canine papillomavirus; Generalities; Lesions related to CPV.

Submitted: 2023-01-01

Accepted: 2023-06-19

Published: 2023-06-23

Additional information and declarations
can be found on page 11

© Copyright 2023

Guillermo Cano-Verdugo *et al.*

open access 



Distributed under Creative Commons CC-BY 4.0

Cite this as:

Cano-Verdugo G, Verdugo-Lizárraga GG, Gámez-Sánchez DE. Generalities in canine papillomavirus: systematic review of case reports. *Veterinaria México OA*. 2023;10. doi: [10.22201/fmvz.24486760e.2023.1160](https://doi.org/10.22201/fmvz.24486760e.2023.1160).

Study contribution

CPV has been under-reported and veterinary medical personnel are unfamiliar with the topic; also, the population demands scientific literature that provides knowledge to the entire medical community. It is imperative to disseminate existing knowledge through systematic reviews that provide data using scientific methods. The results of this research are unique in their nature because they can be used by all veterinary medical fields for interdisciplinary and multidisciplinary collaboration in the development of projects involving the study of CPV.

Introduction

Canine papillomavirus (CPV) is a highly transmissible and common disease in dogs that can cause lesions in various parts of their anatomy.⁽¹⁾ It has been reported in young dogs under 3 years of age and is the main cause of benign epithelial tumors.⁽²⁾ Its early identification can lead to successful treatment and not impair quality of life; however, if not detected early, it serves as a risk factor for the development of squamous cell carcinoma, which has been documented to have a high mortality rate.^(3,4) Currently, the scientific literature on this topic focuses mainly on its detection by visualization and molecular detection and the treatment of papillomatous lesions. The timely knowledge of diseases in dogs is the first link in promoting health in dogs by making it simpler and more effective to reach.^(2,4)

At this time, several authors around the world have explicitly stated the relevance of CPV focusing on its clinical aspects,^(5–7) as an attempt to envision this disease as an area of opportunity to be approached for further study from different spheres of science, however, little is known about the demographic generalities involving this population, the location of lesions and findings involved in their detection,^(8,9) thus, we conducted a systematic review on case reports to shed light on this issues and to summarize the available evidence on generalities in CPV. In this study, we addressed the following question to be answered in this systematic review according to the PICOS framework: In dogs (Population) with CPV (Intervention), compared to those without it (Comparator), what are the generalities related to this virus with respect to the sociodemographic profile, location of lesions, and findings (Outcomes) in case reports (Study design)?

Materials and methods

The present study adhered to the recommendations of the Preferred Reporting Items for Systematic Reviews and Meta-Analyses (PRISMA) statement for systematic reviews,⁽¹⁰⁾ where the proposed methodology was followed using a checklist of guidelines, which was strictly followed in this work. At all times, the information collected was verified in the peer review process. In agreement with the PRISMA-P statement, a protocol was elaborated to serve as a basis for the present systematic review, which is available on the website https://osf.io/rqn7j/?view_only=9a8722a800c24a77bd7e90c415c31a3

Table 1. Search strategies in databases

Source	Search strategies	Articles
PubMed	((“canine s”[All Fields] OR “dogs”[MeSH Terms] OR “dogs”[All Fields] OR “canine”[All Fields] OR “canines”[All Fields]) AND “papillomaviridae”[MeSH Terms] AND (“case reports”[Publication Type] OR “case report”[All Fields])) AND (2012:2022[mdat])	26
DOAJ	canine papillomavirus AND case report	24
CAB Abstracts	[All: case report] AND [All: canine] AND [All: papillomavirus]	4

Eligibility and exclusion criteria, information sources, and search strategy

Eligibility and exclusion criteria were assessed through the PICO-S framework. Detailed information is summarized in supplementary data.

Existing literature was reviewed from 2011 to 2022. The databases reviewed were PubMed, Directory of Open Access Journals (DOAJ), and CAB Abstracts. Medical subject heading (MeSH) terms and boolean operators were applied to PubMed. For DOAJ and CAB Abstracts, only boolean operators were employed because the title did not have MeSH terms and the search could not be executed properly. The search for information in the gray literature was omitted. The search in the databases was performed under the approach described in [Table 1](#).

The selection of studies

Regarding the inclusion criteria, we selected scientific research that addressed CPV in the title or abstract. The last search was performed on 30 December 2022. The articles were selected according to a rubric containing the inclusion criteria and underwent a sequential screening process always performed by peers through the analysis of the title, abstract, and full text. Additionally, the quality of evidence was assessed according to the design of the full text case reports analyzed using the CARE guidelines checklist.⁽¹¹⁾

Data extraction

The data analysis was synthesized narratively, and the results were tabulated individually. A table was made in Excel software, where the main characteristics of each publication were placed: article number, reference, year, country, age, sex, race of the patient, location of the papillomatous lesions, objective, results, conclusions, and findings.

Data synthesis

The information is summarized in tables and compared. Percentages were used as the main summary measures.

The risk of bias assessment of individual studies

Two reviewers involved in this study assessed the risk of bias at the result level using the ROBINS (Risk Of Bias In Non-randomized Studies) tool and the Excel template proposed by Higgins et al.⁽¹²⁾ Domains were included as follows: D1: Does not apply (the randomization process). D2: Does not apply (deviations from intervention). D3: The study describes in sufficient detail a complete case report of a dog with CPV to allow the scientific community to make inferences related to their own practice (missing outcome data). D4: The patient represents the whole experience of the investigator (measurement of the outcome). D5: The study presents a complete section of results with findings, is adequately ascertained, and there were other alternative causes that may explain the observation ruled out (reported results).

Data were uploaded to the *robvis* website (<https://mcguinlu.shinyapps.io/robvis/>), allowing the production of high-quality figures (Traffic-light plot and Summary plot) that encompass the risk of bias assessments. The risk of bias was performed per research article and in general.

Results

The literature search yielded 54 articles related to the topic of interest: 26 in PubMed, 24 in DOAJ, and 4 in CAB Abstracts. Among the total number of articles, none was eliminated for being duplicated in the databases; therefore, 54 articles were analyzed in text and abstract, of which 32 were eliminated because they were not in line with the interests of the present investigation. The remaining 22 articles were analyzed in title and full text, of which 11 were eliminated because they did not address topics related to CPV; therefore, 11 articles were included in the final review. A flow diagram representing the screening and selection process is presented in [Figure 1](#).

The 11 articles included in this systematic review corresponded to research from 9 countries (USA, Japan, Switzerland, Canada, New Zealand, Brazil, Nigeria, India, and France), from 2011 due to the fact that publications before that date did not state that they were case reports in their title and were excluded from the search, mainly due to the publication of CARE guidelines in 2013 that requested primarily to specify the title followed by the words "case report". All the literature collected was in English. The most relevant information is presented below and can be found in [Table 2](#).

The risk of bias within studies

Regarding general bias analysis, among the 11 included studies, only one was classified as high risk (9.10%), four with some concerns (36.36%) and five with low risk (45.45%) ([Figure 2](#)).

When risk analysis by domain was carried out, the following results were found: D1: Not applicable, D2: Not applicable, D3: 70% low risk, 25% some concerns and 5% high risk, D4: 80% low risk and 20% some concerns, D5: 80% low risk and 20% some concerns. A summary of the risk of bias assessment figure can be found in supplementary data.

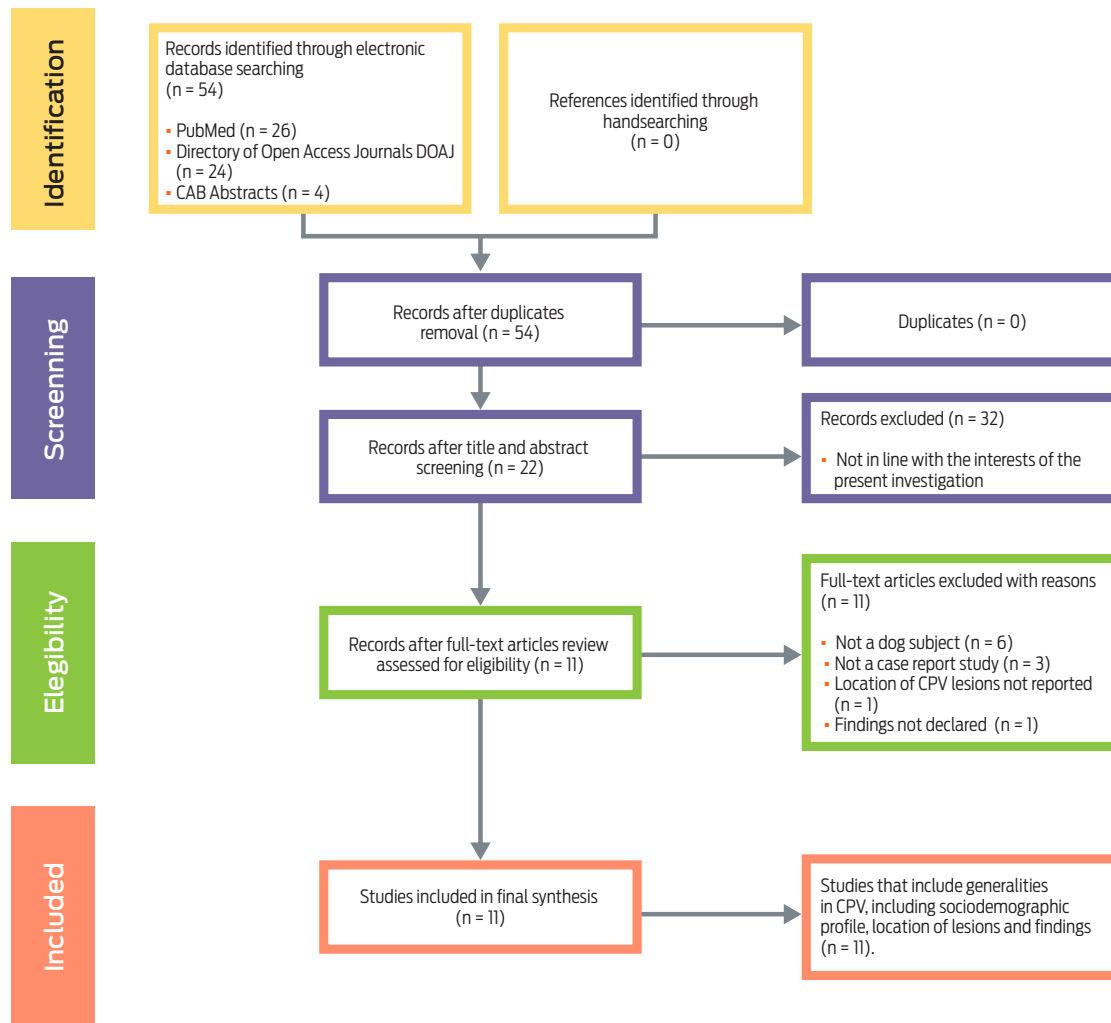


Figure 1. Study selection flowchart.

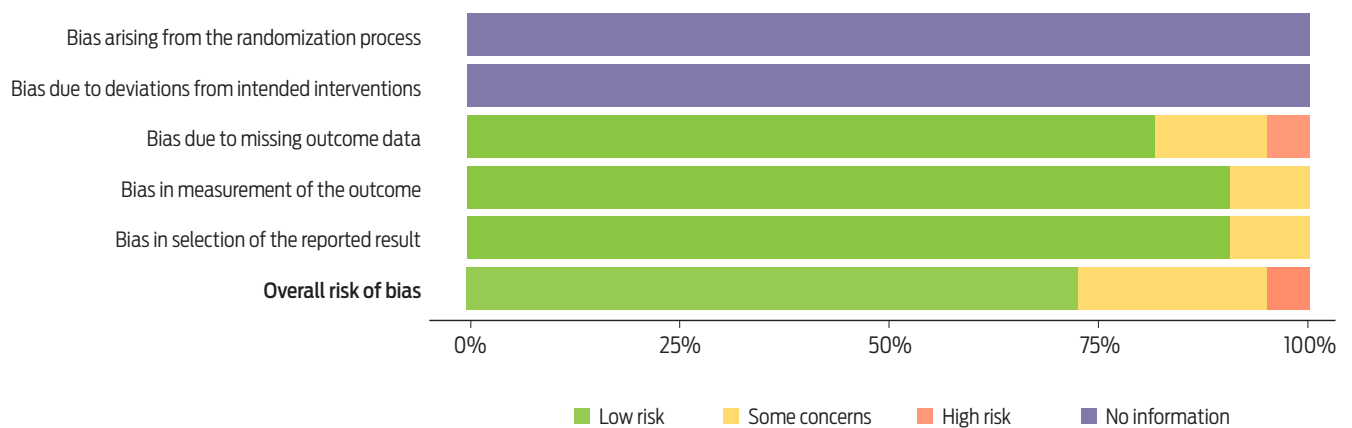


Figure 2. Study-specific risk of judgment.

Table 2. Main results of the literature

Reference	Year/ Country	Age/Sex/Dog breed	The location of lesions	Objective	Results	Conclusions	Findings
Iyori et al., 2019	2019 Japan	A 9-year-old, male, French bulldog	■ Footpads	To describe a case of papillomavirus type 2 related papillomatosis on footpads in a dog	The full genome sequence of CPV-2 in the subject showed 99.95% nucleotide identity with that of CPV-2 from the reference data	In nonimmunocompromised dogs, CPV-2-related footpad papillomatosis could spontaneously resolve after a biopsy	Two weeks after a biopsy, the skin lesion spontaneously regressed without any specific treatment
Lange et al., 2012	2011 Switzerland	A 2-year-old, female, Dachshund-mix	■ Elbow	To apply, describe and test the use of recent data and techniques to assess a putative case of papillomatosis in a dog	The presence of viral DNA was confirmed in the lesions by hybridization with specific probes	CPV8 may be regarded as the fourth member of the Chi-papillomavirus genus. Genomic sequences can be useful in predicting the clinical features of CPV infection	Viruses belonging to this genus induce pigmented plaques in dogs
Luff et al., 2016	2016 USA	A 9-year-old, sex unspecified, Basenji	■ Extremities ■ Head ■ Face ■ Body	To report the progression of PV-associated pigmented plaques to metastatic squamous cell carcinoma	Strong nuclear immunoreactivity inside keratinocytes from pigmented plaques in both dogs was detected by PV antigen immunohistochemistry, supporting an active viral infection.	More compelling proof of a causal relationship would require more information about the capacity of viral oncogenes to change cells.	Although these findings imply a connection between canine CPV infection and malignant transformation, they are by no means conclusive.
Malsawmsangi et al., 2019	2019 India	Not specified	■ Anal region	To describe a case with multiple growths on the skin	Clinical examination revealed multiple papillomatous outgrowths on the skin surface under the tail near the anal region	Histopathological examination is needed to confirm a lesion as papilloma	The surface was hard and thick nodules with horn like projection
Munday et al., 2015	2015 New Zealand	A 7-year-old, intact male, Labrador	■ Oral cavity ■ Mucosa	To describe multiple oral carcinomas associated with a novel papillomavirus in a dog	Sequencing revealed that the DNA was from a novel PV that appears most closely related to canine PV-2 and -7	Whether the PV infection influenced neoplasm development cannot be definitively determined in this case	The presence of p16 immunostaining and the development of multiple oral carcinomas support the role of the PV in tumorigenesis in this dog
Nwoha et al., 2013	2013 Nigeria	Four indigenous breeds of dogs between the ages of 4-5 months	■ Corners of the mouth	To review the importance of surgical intervention on papillomatosis	Papilloma growth is frequently surgically removed by dog owners, ostensibly for aesthetic reasons, which can occasionally be harmful, especially for older dogs.	The majority of canine oral papillomatosis regresses naturally without therapy, although there are drugs available for its treatment.	Dogs should be under veterinarian care for prompt treatment when oncogenic cells invade growth.

Reference	Year/Country	Age/Sex/Dog breed	The location of lesions	Objective	Results	Conclusions	Findings
Regalado Ibarra et al., 2018	2018 Canada	A 3-year-old, male, Labrador retriever (neutered)	■ Upper and lower jaws	To discuss the possible causes of chronic infection and factors that have contributed to OSCC	The presence of CPV-1 DNA in OSCC suggests that this virus might play a significant role in OSCC	A nonregressive, refractory oral CPV-1 infection in a dog where the presence of co-infection by other PVs can be excluded	After 18 months, the patient developed OSCC within of the oral papillomas
Richman et al., 2017	2017 USA	A 1.5-year-old, neutered, French bulldog A 2.5-year-old, neutered Golden retriever A 4-year-old, neutered, Maltese terrier	■ Face ■ Legs ■ Gum	To describe the history, lesions, and therapeutic outcomes of three dogs with persistent viral papillomas.	Using cryotherapy, all lesions in each case healed. One round of treatment was needed in two cases, while two courses were needed in one case.	Cryotherapy may be an effective therapeutic option for canine papilloma lesions that refuse to go away, as seen by the obvious clearance of these lesions.	To conclusively show that this form of therapy, like other therapeutic methods, is actually successful, large-scale clinical investigations are necessary.
Sumathi et al., 2019	2019 India	A 3-year-old, male Labrador retriever	■ Face ■ Extremities ■ Periocular ■ Ears ■ Tail	To review the management of cutaneous papilloma in a dog	The dog was treated with Thuja ointment topically, and thuja oral drops, Immunol® syrup and supportive medication. Regression of skin lesions was observed after 20 days of therapy	Papillomas may originate as solitary cutaneous growth or multiple oral papillomas, and may even appear on genital (venereal), eyelids, and conjunctival areas based on variant of CPV affected	Often lesions may disappear spontaneously as the animal acquires immunity
Valle, 2021	2020 Brasil	A 3-year-old, female, Pug	■ Mouth ■ Tongue	To report the oral papillomatosis treatment in two young dogs	Homeopathic therapy combined with injectable and oral administration of <i>Thuja occidentalis</i> and <i>Viscum album</i> shows excellent results in disease resolution	The combination of the homeopathic medicines <i>T. occidentalis</i> and <i>V. album</i> showed excellent effects in treating canine oral papillomatosis.	Further studies combining both medicines are recommended to confirm this activity in other patients
Yu et al., 2019	2019 Japan	Pug, age and sex unspecified A 11-year-old, Yorkshire terrier	■ Forelimb ■ Lower abdomen ■ Nipple ■ Forelimb	To examine four dogs for CPV genotype and 59 viral localizations in the lesions	In one dog, a neoplastic lesion developed in association with 60 pigmented viral plaque	The CPV18 gene was also detected in a lesion of cytokeratin-14-29 and P63-positive basal cell tumor that developed adjacent to a pigmented viral plaque	This is the first report of basal 32 cell tumor associated with CPV18 infection in dogs, which may be associated with the development of basal cell tumor

OSCC: Oral squamous cell carcinoma.

Sociodemographic profile of the population

The literature refers to case reports with 4 male dogs, 2 female dogs, and 5 of unspecified sex (some articles had more than one case reported). Ages ranged from 2 to 12 years, with those younger than 3 years being the most prevalent group.^(13–16) Case reports were documented in the breeds Dachshund-mix, Yorkshire terrier, Labrador retriever, English pointer, French bulldog, Shih tzu, Chihuahua, Basenji, Staffordshire Bull terrier, Pug, French bulldog, Golden retriever, and Maltese terrier. The breed with the most reported cases was Labrador retriever.^(6, 14, 17, 18) Among the 11 articles collected, 6 reported cases with castrated patients.^(2, 14, 18–20)

The location of lesions

All articles considered in the present systematic review reported papillomatous lesions in various parts of the body, including elbow, forelimb, lower abdomen, nipple, upper and lower jaw, hindlimb, gingiva, footpads, oral cavity, oral mucosa, upper lip, extremities, head, face, body, anal region, corners of the mouth, tongue, extremities, periocular areas, ears, and tail. The most frequent site reported was the oral cavity in general.^(6, 14, 15, 19, 21)

Findings

Unlike Human Papillomavirus (HPV), where more than 200 subtypes have been reported, in CPV only about eight have been reported, all attributable to the induction of pigmented plaques in dogs. There is scientific evidence supporting the documentation of new subtypes such as CPV17 and CPV18, which may be associated with the development of basal cell tumor.^(6–22) Also, postoperative follow-up of patients who have undergone surgical excision of papillomatous lesions is essential because there may be remission with oral squamous cell carcinoma (OSCC) development, especially in the mouth.^(18–22) On the other hand, the authors report surgical excision as the treatment itself since spontaneous remission after the procedure has been reported.⁽²³⁾

In addition to the above, immune status in patients is stated as a key factor in the presence of such lesions, with those with low CD4 and CD8 lymphocyte counts being susceptible to a higher risk of developing papillomatous lesions.^(2, 20, 24) Alternatively, the data provided by Valle,⁽¹⁵⁾ on the treatment of papillomatous lesions through the use of *Thuja occidentalis*, a tree species of the Cupressaceae family, is noteworthy, mentioning that its injectable application shows excellent results in the resolution of the disease.

Discussion

In the present study, majority of CPV case reports were found in patients younger than 3 years of age, which agrees with authors such as Chang et al.⁽²⁵⁾ and Sharma et al.,⁽²⁶⁾ who state that this pathology is mainly found in young dogs. Secondly, here it was found that males and females are equally affected and there is no predilection of CPV with respect to sex, the above is congruent with that reported by

previous studies such as Putnová et al.,⁽²⁷⁾ and Braley and Luff,⁽²⁸⁾ that recognize no predilection of CPV and certain sociodemographic characteristics among them sex, however, it disagrees with authors such as Thaiwong et al.,⁽²⁹⁾ who say that sex is determinant, being male the most affected. In terms of age, the data from Braley and Luff⁽²⁸⁾ are opposite to those found here, as they report a higher prevalence of lesions derived from CPV in mature patients.

Regarding the location of papillomatous lesions, there is little literature about it; however, we find the data of Putnová et al.⁽²⁷⁾ and Raj et al.,⁽⁴⁾ who stipulated the oral cavity including all its structures (gingiva, tongue, and palate) as the most prevalent site of this type of lesions, data reported in the same way in this study. Concerning the appearance of papillomatous lesions, it is essential to mention that in the present study certain authors found that these lesions can be eradicated spontaneously without specifying a time interval,^(17,24) this data should be generalized with caution, because even within the studies collected here the information is contrasting^(13–15,21,30,31) and in other databases where it is mentioned that these lesions may not be eliminated by themselves, but increase in size over time.^(29,32,33)

As it confers the treatment of CPV, the literature is ambiguous. In the present systematic review, it was found that surgical intervention in patients affected with CPV is a viable choice,⁽²¹⁾ and the use of *T. occidentalis* as alternative treatment; however, there is no further information on this subject. In addition to the previous treatment, the authors mention pharmacological treatments specifically with azithromycin and a combination of topical antibiotic and steroids.^(34–36) Nicholls and Stanley⁽³⁷⁾ also express electrosurgery as treatment and declare no preference for CPV and breed of dog.⁽³⁸⁾ It is worth noting that the use of substances as homeopathic treatment for CPV is a little-documented finding.⁽¹⁵⁾ Furthermore, there are authors who have documented the resolution of papillomatous warts even without treatment. In consensus of the authors of the present study, this information cannot be discussed so vaguely, so the panorama is open to continue deepening in this aspect.

Canine papillomavirus subtypes have been an active area of research in this field, so authors such as Lange et al.⁽¹³⁾ and Zhou et al.,⁽¹⁾ report CPV subtypes 17 and 18 in dogs as the most prevalent; however, authors such as Zhou et al.,⁽³⁹⁾ Tisza et al.,⁽⁴⁰⁾ Regalado Ibarra et al.,⁽¹⁴⁾ and Malsawmsangi and Dawngliana,⁽³⁰⁾ who argue the detection of subtypes 1, 6, 12 data not found in the present systematic review. Similarly, Oğuzoğlu et al.⁽⁴¹⁾ manifested CPV type 1 as the most prevalent; however, highlights the fact of being breeds of dogs with pedigree registration, hypothesizing the increase of this condition in purebred dogs. This last data has not been found in the literature collected in this systematic review and constitutes an area of opportunity for researchers interested in the area to increase the existing knowledge regarding CPV and pure breeds.

Limitations

The main limitations of this study is the scarce bibliography found, some investigations were not indexed in the Journal Citation Reports (JCR), and others were ten years or older. On the other hand, it is considered a limitation not to have included case reports that were presented on the web pages of veterinary colleges and

associations, which although they presented a case of a patient with CPV, did not have the scientific rigor required for a scientific publication. Also, there were case reports found in discussion forums by veterinary medical personnel, but they did not present a proposed methodology and sometimes even photographs.

It can also be considered a limitation not to have included unpublished material such as these, dissertations, and school projects that can contribute reliable information to the present study. This systematic review makes available to the scientific community an easy understanding of the generalities related to CPV that are directly linked to veterinary clinical practice.

Conclusions

This systematic review highlights the poor scientific evidence surrounding this canine health problem. However, these results show that canine papillomavirus is a viral entity that has no gender, age, or racial predilection, and its most reported clinical manifestations are papillomatous lesions mainly in the oral cavity with a non-stable treatment, which reflects the need for further research on this topic.

The full knowledge of generalities about reported cases of CPV is of vital importance as a tool to raise awareness of infrequent and unnoticed pathologies in a vulnerable population such as dogs that can cause the formation of small warts or tumors on the skin and mucous membranes. Although most cases are self-limiting and resolve on their own, some infections may require treatment. There are some documented types of this virus such as 1, 6, 16, 18; however, the differentiation between high and low risk has not yet been established.

Future researchers interested in the subject should direct their projects to generate literature that allows establishing a health diagnosis in different cohorts, such as epidemiological studies first and then experimental studies. On the other hand, inter- and multidisciplinary work is highly advisable, since it is a pathology mainly located in the oral cavity and with repercussions at a general level, efforts of all areas of medical sciences with veterinary medical personnel can achieve great results.

Data availability

All data and material are available from the corresponding author upon request.

Acknowledgments

The authors would like to thank the Editorial Board of *Veterinaria México OA* journal for their recommendations on this research.

Funding statement

This research was self-funded and did not receive any specific grant from funding agencies.

Conflicts of interest

The authors declare that they have no conflict of interest concerning this article's research, authorship, and/or publication.

Author contributions

Conceptualization: G Cano-Verdugo

Data curation: GG Verdugo-Lizárraga, DE Gámez-Sánchez

Formal analysis: GG Verdugo-Lizárraga

Funding acquisition: GG Verdugo-Lizárraga

Investigation: G Cano-Verdugo

Methodology: G Cano-Verdugo

Project administration: G Cano-Verdugo

Resources: DE Gámez-Sánchez

Software: DE Gámez-Sánchez

Supervision: DE Gámez-Sánchez

Validation: G Cano-Verdugo, GG Verdugo-Lizárraga

Visualization: GG Verdugo-Lizárraga

Writing – original draft: GG Verdugo-Lizárraga

Writing – review and editing: G Cano-Verdugo, DE Gámez-Sánchez

References

1. Zhou D, Luff J, Paul S, Alkhalawi F, Usuda Y, Wang N, Affolter V, Moore P, Schlegel R, Yuan H. Complete genome sequence of canine papillomavirus type 12. *Genome Announcements*. 2015;3(2):e00294-15. doi: 10.1128/genomeA.00294-15.
2. Cavana P, Hubert B, Cordonnier N, Carlus M, Favrot C, Bensignor E. Generalized verrucosis associated with canine papillomavirus 9 infection in a dog. *Veterinary Dermatology*. 2015;26(3):209–210. doi: 10.1111/vde.12200.
3. Lange CE, Diallo A, Zewe C, Ferrer L. Novel canine papillomavirus type 18 found in pigmented plaques. *Papillomavirus Research*. 2016;2(1):159. doi: 10.1016/j.pvr.2016.08.001.
4. Raj PAA, Pavulraj, S, Kumar MA, Sangeetha S, Shamugapriya R, Sabithabanu S. Therapeutic evaluation of homeopathic treatment for canine oral papillomatosis. *Veterinary World*. 2020;13(1):206–213. doi: 10.14202/vetworld.2020.206-213.
5. Bhatta TR, Chamings A, Vibin J, Alexandersen S. Detection and characterisation of canine astrovirus, canine parvovirus and canine papillomavirus in pup-

- pies using next generation sequencing. *Scientific Reports*. 2019;9(1):4602. doi: 10.1038/s41598-019-41045-z.
6. Munday JS, Lam ATH, Sakai M. Extensive progressive pigmented viral plaques in a Chihuahua dog. *Veterinary Dermatology*. 2022;33(3):252–254. doi: 10.1111/vde.13056.
 7. Anis EA, Frank LA, Francisco R, Kania SA. Identification of canine papillomavirus by PCR in Greyhound dogs. *PeerJ*. 2016;4:e2744. doi: 10.7717/peerj.2744.
 8. Cruz-Gregorio A, Aranda-Rivera AK, Pedraza-Chaverri J. Pathological similarities in the development of papillomavirus-associated cancer in humans, dogs, and cats. *Animals*. 2022;12(18):2390. doi: 10.3390/ani12182390.
 9. Wypij JM. A naturally occurring feline model of head and neck squamous cell carcinoma. *Pathology Research International*. 2013;2013:502197. doi: 10.1155/2013/502197.
 10. Rethlefsen ML, Kirtley S, Waffenschmidt S, Ayala AP, Moher D, Page MJ, Koffel JB. PRISMA-S: an extension to the PRISMA statement for reporting literature searches in systematic reviews. *Systematic Reviews*. 2021;10(1):39. doi: 10.1186/s13643-020-01542-z.
 11. Riley DS, Barber MS, Kienle GS, Aronson JK, von Schoen-Angerer T, Tugwell P, Kiene H, et al. CARE guidelines for case reports: explanation and elaboration document. *Journal of Clinical Epidemiology*. 2017;89(2):218–235. doi: 10.1016/j.jclinepi.2017.04.026.
 12. Higgins JPT, Altman DG, Gøtzsche PC, Jüni P, Moher D, Oxman AD, Savović J, Schulz KF, Weeks L, Sterne JAC. The Cochrane Collaboration's tool for assessing risk of bias in randomised trials. *BMJ*. 2011;343:d5928. doi: 10.1136/bmj.d5928.
 13. Lange CE, Tobler K, Lehner A, Vetsch E, Favrot C. A case of a canine pigmented plaque associated with the presence of a Chi-papillomavirus. *Veterinary Dermatology*. 2012;23(1):76-e19. doi: 10.1111/j.1365-3164.2011.01007.x.
 14. Regalado Ibarra AM, Legendre L, Munday JS. Malignant transformation of a canine papillomavirus type 1-induced persistent oral papilloma in a 3-year-old dog. *Journal of Veterinary Dentistry*. 2018;35(2):79–95. doi: 10.1177/0898756418774575.
 15. Valle ACV. Homeopathic treatment of oral papillomatosis in dogs (*Canis familiaris*)-Case Report. *International Journal of Science and Research*. 2021;10(9), 487–491. doi: 10.21275/SR21907103139.
 16. Richman AW, Kirby AL, Rosenkrantz W, Muse R. Persistent papilloma treated with cryotherapy in three dogs. *Veterinary Dermatology*. 2017;28(6):625-e154. doi: 10.1111/vde.12469.
 17. Sumathi D, Ramesh P, Pazhanivel N, Bhavani MS, Singh KA, Jayathangaraj MG. Management of cutaneous papilloma in a Labrador dog-a case report. *Indian Veterinary Journal*. 2019;96(12):42–43.
 18. Munday JS, Tucker RS, Kiupel M, Harvey CJ. Multiple oral carcinomas associated with a novel papillomavirus in a dog. *Journal of Veterinary Diagnostic Investigation*. 2015;27(2):221–225. doi: 10.1177/1040638714567191.
 19. Gang D-G, Sim C-H, Lee T-J, Kong J-Y, Hong I-H. Sebaceous cell differentiation in a canine oral papilloma. *Journal of Veterinary Diagnostic Investigation*. 2018;30(4):569–571. doi: 10.1177/1040638718779102.

20. Orbell HL, Munday JS, Orbell GMB, Griffin CE. Development of multiple cutaneous and follicular neoplasms associated with canine papillomavirus type 3 in a dog. *Veterinary Dermatology*. 2020;31(5):401–403. doi: 10.1111/vde.12872.
21. Nwoha RI. A case report on natural regression of oral papillomatosis in a dog. *International Journal of Microbiology Research and Reviews*. 2015;4(1):127–129.
22. Yu M, Chambers JK, Tsuzuki M, Yamashita N, Ushigusa T, Haga T, Nakayama H, Uchida K. Pigmented viral plaque and basal cell tumor associated with canine papillomavirus infection in Pug dogs. *Journal of Veterinary Medical Science*. 2019;81(11):1643–1648. doi: 10.1292/jvms.19-0384.
23. Munday JS, Dunowska M, Laurie RE, Hills S. Genomic characterisation of canine papillomavirus type 17, a possible rare cause of canine oral squamous cell carcinoma. *Veterinary Microbiology*. 2016;182(1):135–140. doi: 10.1016/j.vetmic.2015.11.015.
24. Iyori K, Inai K, Shimakura H, Haga T, Shimoura H, Imanishi I, Imai A, Iwasaki T. Spontaneous regression of canine papillomavirus type 2-related papillomatosis on footpads in a dog. *Journal of Veterinary Medical Science*. 2019;81(6):933–936. doi: 10.1292/jvms.19-0136.
25. Chang C-Y, Chen W-T, Haga T, Yamashita N, Lee C-F, Tsuzuki M, Chang H-W. The detection and association of canine papillomavirus with benign and malignant skin lesions in dogs. *Viruses*. 2020;12(2):170. doi: 10.3390/v12020170.
26. Sharma S, Boston SE, Skinner OT, Perry JA, Verstraete FJ, Lee DB, et al. Survival time of juvenile dogs with oral squamous cell carcinoma treated with surgery alone: a Veterinary Society of Surgical Oncology retrospective study. *Veterinary Surgery*. 2021;50(4):740–747. doi: 10.1111/vsu.13625.
27. Putnová B, Burová J, Georgiou M, Fichtel T, Stehlík L, Frgelecová L, Škorič M. Occurrence site of canine oral lesions: a retrospective study of 659 cases. *Acta Veterinaria Brno*. 2020;89(2):179–187. doi: 10.2754/avb202089020179.
28. Bradley CW, Luff JA, Mauldin EA. Clinicopathological findings of canine seborrheic keratosis with comparison to pigmented viral plaques. *Veterinary Dermatology*. 2013;24(4):432-e95. doi: 10.1111/vde.12039.
29. Thaiwong T, Sledge DG, Wise AG, Olstad K, Maes RK, Kiupel M. Malignant transformation of canine oral papillomavirus (CPV1)-associated papillomas in dogs: An emerging concern? *Papillomavirus Research*. 2018;6:83–89. doi: 10.1016/j.pvr.2018.10.007.
30. Malsawmsangi L, Dawngliana MS. Pathomorphological study on canine papilloma: a case report. *Pharma Innovation*. 2019;8(7):726–727.
31. Luff J, Rowland P, Mader M, Orr C, Yuan H. Two canine papillomaviruses associated with metastatic squamous cell carcinoma in two related Basenji dogs. *Veterinary Pathology*. 2016;53(6):1160–1163. doi: 10.1177/0300985816630795.
32. Hansen N, Nicholas N, Pack G, Mackie JT, Shipstone M, Munday JS, Reddell P, Orbell G, Malik R. Progressive cutaneous viral pigmented plaques in three Hungarian Vizslas and the response of lesions to topical tigilanol tiglate gel. *Veterinary Medicine and Science*. 2017;4(1):53–62. doi: 10.1002/vms3.85.
33. Goldschmidt MH, Kennedy JS, Kennedy DR, Yuan H, Holt DE, Casal ML, Traas AM, Mauldin EA, Moore PF, Henthorn PS, Hartnett BJ, Weinberg KI, Schlegel R, Felsburg PJ. Severe papillomavirus infection progressing to metastatic squa-

- mous cell carcinoma in bone marrow-transplanted X-linked SCID dogs. *Journal of Virology*. 2006;80(13):6621–6628. doi: 10.1128/JVI.02571-05.
34. Yağci BB, Ural K, Öcal N, Haydardedeoğlu AE. Azithromycin therapy of papillomatosis in dogs: a prospective, randomized, double-blinded, placebo-controlled clinical trial. *Veterinary Dermatology*. 2008;19(4):194–198. doi: 10.1111/j.1365-3164.2008.00674.x.
 35. Williams A, Scally G, Langland J. A topical botanical therapy for the treatment of canine papilloma virus associated oral warts: A case series. *Advances in Integrative Medicine*. 2021;8(2):151–154. doi: 10.1016/j.aimed.2020.12.003.
 36. Fantini O, Vidémont E, Pin D. Successful treatment of florid papillomatosis in a dog using subcutaneous feline recombinant interferon- ω . *Revue de Médecine Vétérinaire*. 2015;166(1-2):25–29.
 37. Nicholls PK, Stanley MA. Canine papillomavirus—A centenary review. *Journal of Comparative Pathology*. 1999;120(3):219–233. doi: 10.1053/jcpa.1998.0278.
 38. Gould AP, Coyner KS, Trimmer AM, Tater K, Rishniw M. Canine pedal papilloma identification and management: a retrospective series of 44 cases. *Veterinary Dermatology*. 2021;32(5):509-e141. doi: 10.1111/vde.12999.
 39. Zhou D, Wang A, Maxwell S, Schlegel R, Yuan H. Long-term culture of canine ocular cells that maintain canine papillomaviruses. *Viruses*. 2022;14(12):2675. doi: 10.3390/v14122675.
 40. Tisza MJ, Yuan H, Schlegel R, Buck CB. Genomic sequence of canine papillomavirus 19. *Genome Announc*. 2016;4(6):e01380-16. doi: 10.1128/genomeA.01380-16.
 41. Oğuzoğlu TÇ, Timurkan MÖ, Koç BT, Alkan F. Comparison of genetic characteristics of canine papillomaviruses in Turkey. *Infection, Genetics and Evolution*. 2017;55:372–376. doi: 10.1016/j.meegid.2017.10.010.